

# Concurrent Type 2 Diabetes and Multiple Endocrine Neoplasia Type 1 With a Novel MEN1 Gene Mutation

Joung Wook Yang<sup>a</sup>, Su Kyoung Kwon<sup>a, c</sup>, Jeong Hoon Kim<sup>b</sup>, Young Sik Choi<sup>a</sup>, Yo-Han Park<sup>a</sup>

## Abstract

Multiple endocrine neoplasia type 1 (MEN1) is an autosomal dominant inherited disorder that is characterized by the combined occurrence of primary hyperparathyroidism (PHPT), enteropancreatic neuroendocrine tumors and anterior pituitary adenomas. Increased insulin resistance and a higher prevalence of glucose intolerance have been noted in MEN1 families and are associated with increased cardiovascular mortality. Mutations in the *MEN1* tumor suppressor gene cause multiple tumors in MEN1 but can also be associated with glycemic dysregulation. A 52-year-old man was admitted for blood glucose control. He had been diagnosed with diabetes 3 years previously. Hypercalcemia was incidentally detected during a blood test. After examination, he was diagnosed with PHPT caused by parathyroid hyperplasia. On genetic analysis, he was found to have a novel mutation in the *MEN1* gene (exon 10, c.1590\_1606\_del; p.Gly532AlafsX20). We report a case of MEN1 with a novel *MEN1* gene mutation associated with type 2 diabetes in a patient with no family history of diabetes. This is the first case of MEN1 associated with type 2 diabetes before pancreatic surgery in Korea.

**Keywords:** Multiple endocrine neoplasia type 1; Type 2 diabetes mellitus; *MEN1* gene; Primary hyperparathyroidism

## Introduction

Multiple endocrine neoplasia type 1 (MEN1) is an inherited tumor syndrome characterized by tumors of the parathyroid glands, pancreatic endocrine tissues and the anterior pituitary gland, but other tumors such as foregut carcinoids and adrenal adenomas, lipomas and angiofibromas can also be seen [1].

Manuscript accepted for publication October 13, 2014

<sup>a</sup>Department of Internal Medicine, Endocrinology and Metabolism, Kosin University College of Medicine, Busan, Korea

<sup>b</sup>Department of Surgery, Kosin University College of Medicine, Busan, Korea

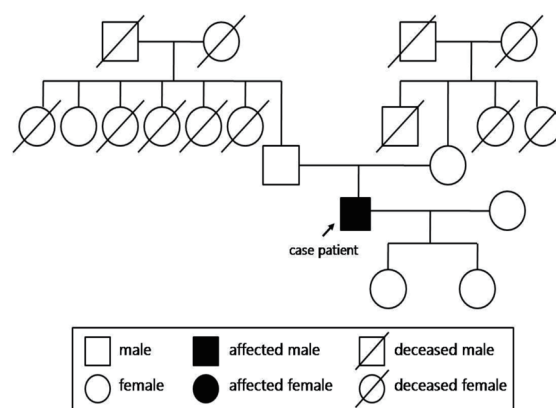
<sup>c</sup>Corresponding Author: Su Kyoung Kwon, Department of Internal Medicine, Gospel Hospital, Kosin University College of Medicine, 34 Amnam-dong, Seo-gu, Busan 602-702, Korea. Email: mir316@naver.com

doi: <http://dx.doi.org/10.14740/jmc1973w>

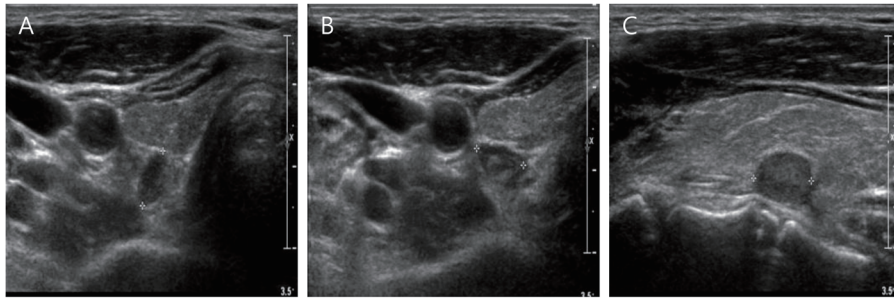
Multiple tumors occur in MEN1 due to a loss of function mutation in the *MEN1* tumor suppressor gene. The *MEN1* gene encodes an amino acid protein, menin [2], a ubiquitously expressed nuclear protein. About 40 different proteins are known to interact with menin, through which menin acts as a transcriptional regulator to either activate or repress gene transcription. Most of the mutations in the *MEN1* gene cause dysfunction of menin. Therefore, dysregulated transcription might lead to tumor formation. Menin also interacts with peroxisome proliferator-activated receptor- $\gamma$  and the vitamin D receptor, which are both associated with glucose metabolism [3]. According to Wagner et al, diabetes and impaired fasting glucose are observed more frequently in MEN1 patients than the general population [4]. In the Korean literature, Oh et al reported the first case of MEN1 in 1986, and a total of 26 cases have been reported since then. However, there have been no reported cases of MEN1 associated with preexisting type 2 diabetes before pancreatic surgery in Koreans. This report describes an MEN1 patient with diabetes who was revealed to have a novel frameshift mutation in the *MEN1* gene.

## Case Report and Genetic Analysis

A 52-year-old man presented with an uncontrolled high blood glucose level. The patient had been diagnosed with diabetes 3



**Figure 1.** Family pedigree.



**Figure 2.** Thyroid ultrasonography demonstrates two hypoechoic nodules behind the right thyroid gland and one hypoechoic nodule behind the left thyroid gland (Rt: 0.84 cm, 0.75 cm; Lt: 1.01 cm).

years prior and was taking biguanide and sulfonylurea. He did not have any history of hypertension, tuberculosis, or hepatitis, but he had history of a ureteral stone 3 years prior. He is an only child, and his mother and father, who are both alive, do not have diabetes or a history of hypercalcemia. The patient has two children (Fig. 1). In the neck examination, the thyroid was not enlarged, and there were no palpable tumors. The physical examination of the chest and abdomen was normal.

General biochemical tests showed that fasting blood glucose was 305 mg/dL, blood urea nitrogen was 17 mg/dL, creatinine was 0.7 mg/dL, insulin was 7.24  $\mu$ U/mL, C-peptide was 1.78 ng/mL, HbA1c was 8.9%, albumin was 4.2 g/dL, S-GOT/S-GPT was 18/17 IU/L and alkaline phosphatase was 103 IU/L. Blood electrolyte tests showed that sodium was 142 mEq/L, potassium was 5.2 mEq/L, chloride was 112 mEq/L, blood calcium was 11.6 mg/mL, phosphorus was 2.3 mg/dL and uric acid was 10.2 mg/dL. Urinary calcium excretion was 310 mg/24 h. Intact-PTH was increased at 115.8 pg/mL. Endocrine hormonal studies did not reveal any abnormalities regarding the pituitary (TSH, GH, LH, FSH, and prolactin), pancreas (gastrin, insulin, glucagon, and somatostatin), thyroid, or adrenal gland hormones.

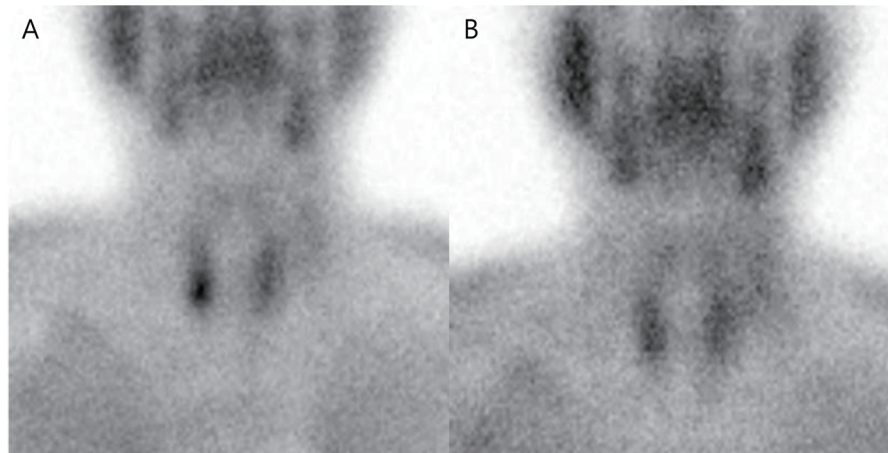
Upon dual X-ray absorptiometry (DXA), the Z-score of the total femur was -1.9, and T-score of total femur was -2.2, confirming the low bone mass expected per age. On neck ultra-

sound, a total of three hypoechoic extra-thyroid nodules were seen at both thyroid beds (Fig. 2). Tc-99m MIBI parathyroid scintigraphy showed radioactive uptake of one nodule at the lower portion of the right thyroid lobe (Fig. 3).

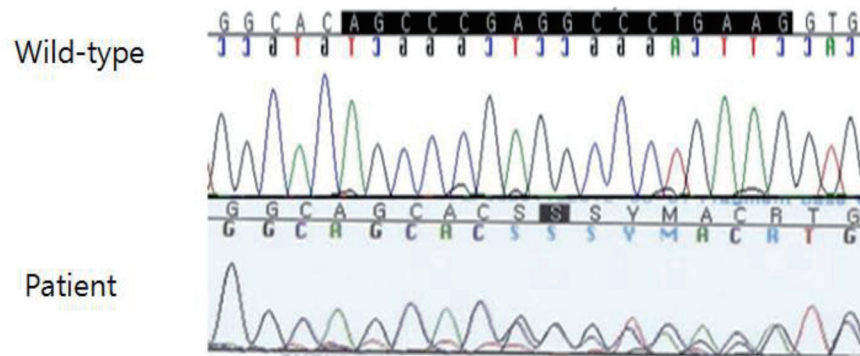
Abnormal findings in the pituitary were not detected on brain magnetic resonance imaging (MRI). The abdominal computed tomography (CT) showed two small cysts in the head and tail of the pancreas with no other abnormalities. Genomic DNA was extracted from the peripheral blood of the patient, and sequencing of the *MEN1* gene was performed. A novel frameshift mutation was identified in exon 10 (c.1590\_1606\_del, p.Gly532AlafsX20) of his genomic DNA (Fig. 4).

For treatment of hyperparathyroidism associated with MEN 1, total parathyroidectomy with sternocleidomastoid muscle (SCM) autotransplantation of the normal appearing parathyroid gland and prophylactic central thymectomy were performed. Postsurgical pathology confirmed a left parathyroid gland adenoma and hyperplasia of the two right parathyroid glands. Two months after surgery, the intact-PTH level decreased to 24.7 pg/mL, the serum calcium level decreased from 11.6 to 10.2 mg/dL and HbA1C was from 8.9% to 6.6%.

We recommended blood electrolyte and genetic testing for his two daughters and parents. However, he refused our recommendation, so we do not know if this was a *de novo* mutation.



**Figure 3.** 99m Tc-tetroformin parathyroid scan. (A) The early image (30 min) showed a nodular hot uptake in the lower portion of the right thyroid lobe. (B) The delayed image (2 h) showed hot uptake in the lower portion of the right thyroid lobe.



**Figure 4.** Sequencing of exon 10 shows a frameshift mutation (c.1590\_1606\_del; p.Gly532AlafsX20). 1590: AGGTGGCAG-CACGGCTC; 1606: AGGTGCCAGCACCCGCA.

## Discussion

MEN1 has an autosomal dominant inheritance with high penetrance [1]. The penetrance of MEN1 is estimated to be approximately 95% at 40 years of age. Primary hyperparathyroidism (PHPT) represents the most common endocrine disorder of MEN1, occurring in more than 95% of patients. MEN1 is associated with a *MEN1* gene mutation. The *MEN1* gene spans 9 kb of the genome and is characterized by 10 exons, which were identified in 1997 [3]. The *MEN1* gene has been cloned on chromosome 11q13 and encodes a 610 amino acid protein called “menin” [3]. Although the functional role of menin remains to be elucidated, it has been suggested to suppress tumorigenesis [2]. *MEN1* gene mutations have been reported in up to 1,133 germline and 203 somatic mutations [5]. The germline mutation at the splice sites of the *MEN1* gene consisted of 23% nonsense mutations, 9% splice site mutations, 41% frameshift deletions or insertions, 6% in-frame deletions or insertions, 20% missense mutations, and 1% whole or partial gene deletions. Of all MEN1 mutations, 75% are inactivating and consistent with those expected in a tumor suppressor gene [5].

A total of 26 MEN1 cases have been reported in Korea so far, of which 12 (46%) have reported analysis of the *MEN1* gene mutation involved. According to the reports of the 12 cases, there have been no cases of MEN1 associated with diabetes [5-12] (Table 1). Upon genetic analysis of the *MEN1* gene mutations reported in Korea and other countries, a novel mutation of the *MEN1* gene (axon10, c.1590\_1606\_del; p.Gly532AlafsX20) was detected in the present patient. Although the association between MEN1 and diabetes in Korea has not been reported to date, several recently published reports have suggested that MEN1 is associated with diabetes [4, 13-15].

Patients with PHPT may have an increased risk of cardiac morbidity such as an increased risk of dyslipidemia, impaired glucose tolerance and type 2 diabetes [16]. There is also some evidence that PHPT in MEN1 patients may be associated with impaired glucose intolerance and type 2 diabetes. Wagner et al described increased insulin resistance in 19 MEN1 patients

from six families. Studies have identified cardiovascular disease as a cause for premature mortality in MEN1 patients [3]. McCallum et al reported that diabetes and impaired fasting glucose occur more frequently among MEN1 patients than controls [15]. Hypercalcemia-induced insulin resistance and a lower threshold for neoplastic secretion of enteropancreatic mediators of insulin resistance such as TNF- $\alpha$ , IL-6, leptin, resistin and adiponectin are potential explanations [15]. Kautzky-Willer et al reported improvement of insulin resistance in PHPT after parathyroidectomy [16].

There are two molecular pathways that associate menin with diabetes in MEN1 patients. First, menin is a co-activator of PRAR- $\gamma$ -mediated gene transcription. It activates PPAR- $\gamma$ -dependent adipocyte differentiation and gene transcription, which increases insulin sensitivity. Second, menin interacts with the vitamin D receptor. It is known that expression of the VDR target is decreased in MEN1-related parathyroid adenoma patients [17] and low vitamin D level is related to increased insulin resistance and increased prevalence of diabetes. Although the patient in this case had no family history of diabetes, he had MEN1 as well as diabetes. It is not clear whether the comorbid disease status is associated with the novel *MEN1* gene mutation or simply associated with the increased diabetes prevalence in MEN1 patients. Further investigation into this specific *MEN1* gene mutation will help clarify the association between MEN1 and diabetes.

Due to the frequent recurrence of hyperparathyroidism in MEN1-associated hyperparathyroidism, the patient underwent total parathyroidectomy with autotransplantation on SCM. PHPT is the most common and often the first manifestation of MEN1. Since PHPT was the first manifestation in this patient, and there was no evidence of other endocrine gland tumors, lifelong surveillance for additional tumor expression will be needed for this case patient.

We report a case of a patient with a novel frameshift mutation of the *MEN1* gene with concurrent type 2 diabetes with no family history of diabetes or known risk factors for diabetes. Even though there is an increased prevalence of diabetes among MEN1 patients, further efforts are needed to investigate whether this novel *MEN1* gene mutation impacts the development of diabetes. We suggest that the ongoing surveillance of

**Table 1.** Summary of 13 Cases of *MEN1* gene Mutation Analysis Reported in Korea and Our Case

Case No.	Sex	Age (years)	Exon	Codon	Mutation	Association tumor	DM	Reference
1	F	22	2	67	Frameshift mutation 200-201insAGCCC	P(1) prolactin+ P(2) (-) P(3) insulin+	No	5
2	M	70	9	383	Point mutation GAC- > CAT	P(1) (-) P(2) adenoma P(3) VIP+	No	6
3			9	405	Nonsense mutation 1213C > T	P(1) prolactin+ P(2) hyperparathyroidism P(3) somatostatin+	Unknown	7
4			2	67	Frameshift mutation 210-211insAGCCC	P(1) non-function P(2) hyperparathyroidism P(3) non-function	Unknown	7
5			7	325	Missense mutation 973G > C	P(1) prolactin+ P(2) hyperparathyroidism P(3) insulin+, glucagon+	Unknown	7
6			7	325	Nonsense mutation 969C > A	P(1) prolactin+ P(2) hyperparathyroidism P(3) insulin+	Unknown	7
7	F	50	7	350	Missense mutation 1159A > T	P(1) non-function P(2) adenoma P(3) non-function	No	8
8	F	82	7	350	Missense mutation 1159A > T	P(1) (-) P(2) adenoma P(3) non-function	No	8
9	M	51	3	215	Missense mutation V215M, GTG- > ATG	P(1) (-) P(2) hyperplasia P(3) non-function	No	9
10	F	42	3	551	Frameshift mutation P551R(del C)	P(1) (-) P(2) hyperplasia P(3) (-)	No	10
11	F	23	1	251	Frameshift mutation c.251_del; Ser84LeufsX35	P(1) prolactin+ P(2) adenoma P(3) insulin+	No	11
12	F	46	3	196	Frameshift mutation 196-200insAGCCC	P(1) non-function P(2) adenoma P(3) calcitonin+	No	12
13	M	52	10	532	Frameshift mutation c.1590_1606_del; p.Gly532AlafsX20	P(1) (-) P(2) adenoma, hyperplasia P(3) non-function	Yes	Our case

P(1): pituitary; P(2): parathyroid; P(3): pituitary; M: male; F: female.



MEN1 patients is necessary with regard to diabetes status.

## References

1. Pannett AA, Thakker RV. Multiple endocrine neoplasia type 1. *Endocr Relat Cancer*. 1999;6(4):449-473.
2. Guru SC, Crabtree JS, Brown KD, Dunn KJ, Manickam P, Prasad NB, Wangsa D, et al. Isolation, genomic organization, and expression analysis of Men1, the murine homolog of the *MEN1* gene. *Mamm Genome*. 1999;10(6):592-596.
3. Agarwal SK. Multiple endocrine neoplasia type 1. *Front Horm Res*. 2013;41:1-15.
4. Wagner AM, Martin-Campos JM, Mayoral C, de Leiva A, Blanco-Vaca F. Patients with MEN-1 are more insulin-resistant than their non-affected relatives. *Eur J Intern Med*. 2005;16(7):507-509.
5. Park SE, Kang ES, Lee HJ, Kim SH, Do MY, Kang SA, et al. A case of multiple endocrine neoplasia type 1 with mutation in MENIN gene. *J Korean Soc Endocrinol*. 2005;20(1):71-77.
6. Lee SW, Choi YS, Park YH, Oh KS, Shin JW, Kim IJ, et al. A case of multiple endocrine neoplasia associated with VIPoma. *J Korean Soc Endocrinol*. 2005;20(1):64-70.
7. Park JH, Kim IJ, Kang HC, Lee SH, Shin Y, Kim KH, Lim SB, et al. Germline mutations of the *MEN1* gene in Korean families with multiple endocrine neoplasia type 1 (MEN1) or MEN1-related disorders. *Clin Genet*. 2003;64(1):48-53.
8. Choi H, Kim S, Moon JH, Lee YH, Rhee Y, Kang ES, Ahn CW, et al. Multiple endocrine neoplasia type 1 with multiple leiomyomas linked to a novel mutation in the *MEN1* gene. *Yonsei Med J*. 2008;49(4):655-661.
9. Choi YS, Bai SY, Ku BJ, Jo YS, Kim YK, RO HK et al. A Case of Multiple Endocrine Neoplasia Type I with Atypical clinical course. *J Korean Endocr Soc*. 2008;23(4):266-271.
10. Kim SW, Lee SJ, KIM HS, Kim JY, Jung ED, Jung DS et al. A Case of Familial Isolated Primary Hyperparathyroidism with a Novel Gene. *Endocrinol Metab*. 2010;25(4):374-377.
11. Kim MJ, Kim EH, Shin MS, Kim JH, Na HK, Park SJ, Lee SA, Koh EH et al. A Case of Familial Multiple Endocrine Neoplasia Type 1 with a Novel Mutation in the *MEN1* gene. *Endocrinol Metab*. 2011;26(2):171-176.
12. Choi JH, Kim HI, Kang SM, Kim SG, Bae SH, Ryoo HM at el. A Case of a Calcitonin-secreting Pancreatic Endocrine Tumor in a Patient with Multiple Endocrine Neoplasia Type 1. *Korean J Med*. 2012;83(6):817-822.
13. Lemos MC, Thakker RV. Multiple endocrine neoplasia type 1 (MEN1): analysis of 1336 mutations reported in the first decade following identification of the gene. *Hum Mutat*. 2008;29(1):22-32.
14. van Wijk JP, Dreijerink KM, Pieterman CR, Lips CJ, Zelissen PM, Valk GD. Increased prevalence of impaired fasting glucose in *MEN1* gene mutation carriers. *Clin Endocrinol (Oxf)*. 2012;76(1):67-71.
15. McCallum RW, Parameswaran V, Burgess JR. Multiple endocrine neoplasia type 1 (MEN 1) is associated with an increased prevalence of diabetes mellitus and impaired fasting glucose. *Clin Endocrinol (Oxf)*. 2006;65(2):163-168.
16. Kautzky-Willer A, Pacini G, Niederle B, Schernthaner G, Prager R. Insulin secretion, insulin sensitivity and hepatic insulin extraction in primary hyperparathyroidism before and after surgery. *Clin Endocrinol (Oxf)*. 1992;37(2):147-155.
17. Dreijerink KM, Varier RA, van Beekum O, Jeninga EH, Hoppener JW, Lips CJ, Kummer JA, et al. The multiple endocrine neoplasia type 1 (MEN1) tumor suppressor regulates peroxisome proliferator-activated receptor gamma-dependent adipocyte differentiation. *Mol Cell Biol*. 2009;29(18):5060-5069.