

Acute Gastric Dysfunction After Catheter Ablation of Atrial Fibrillation

Alicia M. Alvarez^{a, b}, Sandra Rodriguez^a, Kanwarpreet Tandon^a, Roger J. Charles^a

Abstract

Gastroparesis is a chronic disorder characterized by slow gastric emptying in the absence of mechanical obstruction. Rarely, acute cases of gastroparesis can present as an extracardiac complication caused by vagus nerve injury following radiofrequency ablation for the treatment of refractory atrial fibrillation. This presentation is rare and may present a challenge for management since only a few cases have been described in the literature. We report a case of acute delayed gastric emptying as a consequence of percutaneous catheter ablation of atrial fibrillation, which improved after symptomatic treatment with prokinetic agents.

Keywords: Gastroparesis; Delayed gastric emptying; Gastric dysfunction

Introduction

Gastroparesis is a chronic disorder characterized by slow gastric emptying in the absence of mechanical obstruction [1]. Symptoms of gastroparesis are variable, nonspecific and usually include nausea, vomiting, bloating, early satiety and abdominal pain [2]. It has many potential etiologies. The most common causes of gastroparesis are idiopathic, diabetic and postsurgical, although other conditions such as Parkinson's disease and collagen vascular diseases have been associated with symptomatic delayed gastric emptying. Postsurgical gastric dysfunction and overt gastroparesis are well-recognized consequences of therapeutic vagotomy for peptic ulcers or from inadvertent vagal nerve injury after Nissen fundoplication for gastroesophageal reflux disease (GERD). Vagal nerve injury has been reported in 4-40% of patients undergoing laparoscopic fundoplication [3].

Rarely, acute cases of gastroparesis can present as an extracardiac complication caused by vagus nerve injury following radiofrequency ablation for the treatment of refractory atrial fibrillation with the onset of symptoms as early as 3 - 24 hours(h) post-procedure [4]. This presentation is far less common than diabetic and idiopathic gastroparesis and may present a challenge for management since only a few cases have been described in the literature.

Here, we report a case of acute delayed gastric emptying as a consequence of percutaneous catheter ablation of atrial fibrillation, which improved after symptomatic treatment with prokinetic agents.

Case Report

A 47-year-old female, high-performance athlete, with no documented structural heart disease underwent catheter ablation for drug refractory paroxysmal atrial fibrillation (PAF). No complications were detected during procedure, and the patient was discharged home after 24 h of close observation. Seven days later, patient was seen in the Emergency Department with symptoms of worsening upper abdominal fullness and abdominal distention.

On admission, patient denied any nausea, vomiting and/or abdominal pain. Her appetite was decreased, but no weight loss was reported. General examination revealed normal vital signs. Abdominal exam showed a non-tender but distended abdomen; bowel sounds were markedly decreased and positive succussion splash during auscultation. No guarding or rebound tenderness was elicited. The hematological profile, blood sugar, electrolytes, renal function and LFTs were otherwise unremarkable. A CT of abdomen and pelvis with intravenous (IV) and oral contrast showed severe distention of the gastric lumen containing heterogeneous congested material. However, there was no evidence of complete luminal obstruction as contrast material was observed in the mid-ileum (Fig. 1).

A scintigraphic 4 h gastric emptying test (GET) was performed. The patient consumed a standard 300 g meal labeled with ^{3m}CiTe sulfur colloid. 32% of the meal was retained at the end of 4 h (normal < 10% retention at the end of 4 h) (Fig. 2). Diagnosis of gastroparesis was made, a nasogastric tube was inserted and the patient was started on metoclopramide HCL 20 mg IV every 8 h.

Manuscript accepted for publication January 14, 2015

^aDepartment of Gastroenterology, Cleveland Clinic Florida, Weston, FL, USA

^bCorresponding Author: Alicia Alvarez, Department of Gastroenterology, Cleveland Clinic Florida, 2950 Cleveland Clinic Blvd., Weston, FL 33331, USA. Email: alicia.alvarez.md@gmail.com

doi: <http://dx.doi.org/10.14740/jmc2050w>

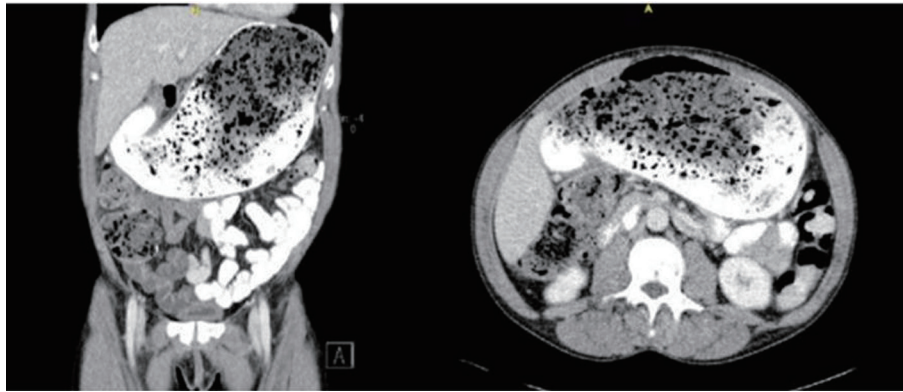


Figure 1. CT scan of abdomen and pelvis showing severe gastric distention with abundant retained heterogeneous material.

On the following day, the patient became less symptomatic with a significant reduction in abdominal distention. On the third day, IV metoclopramide was switched to 10 mg PO before meals. The nasogastric tube had minimal drainage, and she was able to tolerate a liquid diet.

The patient made an excellent recovery and was discharged home with a tapering (4 weeks) course of metoclopramide. After the patient’s oral intake improved, solid food was introduced on day 7 and she was able to tolerate it. The patient did not complain of any gastrointestinal symptoms at the time of follow-up 2 weeks after hospital discharge.

Discussion

Catheter ablation has improved the treatment paradigm of atrial fibrillation, but it may be associated with significant gastrointestinal complications. This case report describes an acute presentation of delayed gastric emptying as an adverse effect of such procedure.

Gastric contractions and subsequent gastric emptying of digested food material to allow nutrient absorption in the small intestine are the main functions of the stomach [5]. These are

controlled by several mechanisms, but most importantly they are modulated by the central nervous system and relayed to the stomach by the vagus nerve; therefore, an intact vagal nerve is required for normal gastric function. The paraesophageal vagal nervous plexus controls gastric peristalsis, gastric motility and the pyloric sphincter. Vagal nerve fibers are thought to descend the esophagus posteriorly to the left atrium and then through the diaphragm into the abdomen within the left vagal trunk [4]. Based on this anatomy, the plexus is at risk of injury when the radiofrequency energy used during catheter ablation is delivered to the left atrial myocardium [6]. Injury leads to acute gastric emptying delay, causing symptoms of gastroparesis similar to those seen in patients with long-standing uncontrolled diabetes.

Due to the anatomic variation of the human vagal nerve plexus around the lower esophagus, it is difficult to predict which patients are at risk during the procedure [6]. As such, the incidence is not well defined. In a recent study, 11 cases of vagal nerve injury were described following ablation out of 3,695 total study population [7]. A larger survey involving 182 centers worldwide, reported no vagal nerve injuries after catheter ablation of atrial fibrillation [8]. The onset of symptoms varies and can occur immediately after the procedure and up to 4 days later [4]. Most patients present for evaluation with the onset of symptoms; however, rarely some may present after several months, with alarming symptoms such as weight loss [6].

In patients with a suggestive history, a high index of suspicion is important for making the diagnosis. A GET should be performed to confirm acute gastric emptying delay. In addition, other causes of such presentation must be ruled out; patients should be screened for diabetes, thyroid disease, GERD and recent viral illnesses. A thorough medication review should also be conducted, paying attention to narcotics and anti-cholinergic agents, which may mimic symptoms of acute gastroparesis [9].

Management is no different to that of other causes of acute gastric emptying delay, and it usually entails a combination of strategies. Restoration of fluid and electrolyte balance should be the initial step. Consumption of small frequent meals that are low fat and fiber has been shown to improve symptoms. Administration of prokinetic agents such as metoclopramide, erythromycin and domperidone are also of benefit in combina-

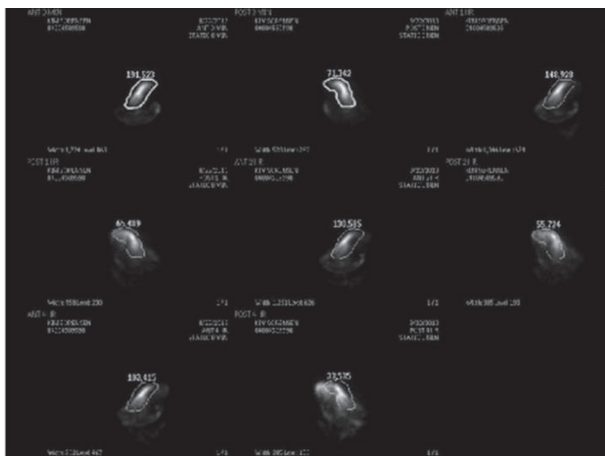


Figure 2. Gastric emptying scintigraphy. There is 75% radiotracer remaining in the stomach at 1 h, 58% at 2 h and 32% at 4 h.

tion with anti-emetic agents [9]. Because pyloric spasm may be a prominent component of this syndrome, endoscopy followed by balloon dilation or by local injection of *Botulinum* toxin can provide relieve in patients with symptoms lasting longer than 4 weeks [7, 10]. Rarely, symptoms may persist over 6 months; in such patients surgery has proven effective [7, 10]. The use of temporary gastric stimulators in patients with long-standing symptoms has not been described.

The chronological symptomatology that results from acute gastric emptying delay following the procedure clearly indicates that this adverse effect is a sequela of atrial ablation. The clinical course and severity of the paraesophageal vagal nerve injury can vary, but most patients recover within 4 - 6 weeks with conservative treatment. As reported in the literature, an earlier onset of symptoms seems to correlate with significant residual gastric motor dysfunction [10]. Also, those patients who present late in their disease course are more likely to be evaluated endoscopically [4].

We describe a rare case of acute gastric emptying delay following catheter ablation for management of refractory PAF. As electrophysiologists continue to use this procedure in the management of atrial fibrillation, such cases will continue to arise. It is our intent to make gastroenterologists aware of this rare complication, to facilitate early initial diagnosis and management.

Abbreviations

GERD: gastroesophageal reflux disease; IV: intravenous; GET: gastric emptying test

References

1. Camilleri M. Clinical practice. Diabetic gastroparesis. *N Engl J Med*. 2007;356(8):820-829.
2. Shafi MA, Pasricha PJ. Post-surgical and obstructive gastroparesis. *Curr Gastroenterol Rep*. 2007;9(4):280-285.
3. Hunter RJ, Metz DC, Morris JB, Rothstein RD. Gastroparesis: a potential pitfall of laparoscopic Nissen fundoplication. *Am J Gastroenterol*. 1996;91(12):2617-2618.
4. Shah D, Dumonceau JM, Burri H, Sunthorn H, Schroft A, Gentil-Baron P, Yokoyama Y, et al. Acute pyloric spasm and gastric hypomotility: an extracardiac adverse effect of percutaneous radiofrequency ablation for atrial fibrillation. *J Am Coll Cardiol*. 2005;46(2):327-330.
5. Koch KL. Diabetic gastropathy: gastric neuromuscular dysfunction in diabetes mellitus: a review of symptoms, pathophysiology, and treatment. *Dig Dis Sci*. 1999;44(6):1061-1075.
6. Choi SW, Kang SH, Kwon OS, Park HW, Lee S, Koo BS, Nam GB. A case of severe gastroparesis: indigestion and weight loss after catheter ablation of atrial fibrillation. *Pacing Clin Electrophysiol*. 2012;35(3):e59-61.
7. Kuwahara T, Takahashi A, Takahashi Y, Kobori A, Miyazaki S, Takei A, Fujino T, et al. Clinical characteristics and management of periesophageal vagal nerve injury complicating left atrial ablation of atrial fibrillation: lessons from eleven cases. *J Cardiovasc Electrophysiol*. 2013;24(8):847-851.
8. Cappato R, Calkins H, Chen SA, Davies W, Iesaka Y, Kalman J, Kim YH, et al. Updated worldwide survey on the methods, efficacy, and safety of catheter ablation for human atrial fibrillation. *Circ Arrhythm Electrophysiol*. 2010;3(1):32-38.
9. Camilleri M, Parkman HP, Shafi MA, Abell TL, Gerson L. Clinical guideline: management of gastroparesis. *Am J Gastroenterol*. 2013;108(1):18-37; quiz 38.
10. McLellan AJ, Kistler PM. Periesophageal vagal nerve injury post-AF ablation: the esophagus a vulnerable neighbor? *J Cardiovasc Electrophysiol*. 2013;24(8):852-854.