

Intravascular Papillary Endothelial Hyperplasia (Masson's Tumor) Found as an Adrenal Incidentaloma

David A. Levine^{a, c}, Richard A. Levine^a, Elvia Goetz-Gutierrez^b

Abstract

Intravascular papillary endothelial hyperplasia (Masson's tumor) is a rare, benign, neoplastic lesion which arises from endothelial proliferation around an existing thrombus. This condition is most commonly found in the head, neck, or extremities. Only four cases of Masson's tumor in the adrenal gland have been reported to date, making this an extremely rare location. When occurring in the adrenal gland, confusion of this neoplasm with highly malignant conditions is common; therefore, Masson's tumor is a diagnosis of exclusion. A case of adrenal intravascular papillary endothelial hyperplasia discovered as an incidental finding on abdominal CT is examined.

Keywords: Masson tumor; Adrenal; Intravascular papillary endothelial hyperplasia; Intravascular

Introduction

Intravascular papillary endothelial hyperplasia (Masson's tumor) was first described in 1923 by Pierre Masson, occurring in a rectal vein. Since its discovery, it has predominantly been found in the oral cavity, head, neck, and extremities [1]. Only four cases occurring in the adrenal gland have been reported to date [2]. Three forms of this lesion exist: primary, secondary, and extravascular. The primary form arises within a normal vessel, whereas secondary develops within a pre-existing vascular malformation (e.g. pyogenic granuloma, cavernous hemangioma), and extravascular develops within a hematoma. Masson's tumor can also be categorized as "pure" or "mixed" forms. "Pure" denotes lesions which form within a normal ves-

sel, and "mixed" represents lesions which form in a vascular malformation [3]. The pathogenesis of Masson's tumor is not entirely known. There are numerous theories as to how the lesion forms and to what is the cause. It is most commonly regarded as a reactive process by the endothelium to an existing thrombus [2]. Histopathologically, the lesion is characterized by blunted papillary projections within a vessel lumen which have a hyalinized core and are associated with a nearby thrombus (Fig. 1). The papillary projections are covered by one or two layers of endothelial cells which lack pleomorphism, anaplasia, increased mitotic activity, necrosis, or significant disorganization, thus differentiating it from an angiosarcoma [4]. Patients commonly present with an asymptomatic growth, but if the lesion is non-superficial, it is often undiagnosed or found incidentally on imaging. Treatment is total excision biopsy and microscopic examination [3]; recurrence is rare.

Case Report

A 56-year-old male presented with hypertension refractory to pharmacological therapy, hot flashes, and sweating for the last 2 years. His past medical history was significant for type 2 diabetes, hyperlipidemia, hypertension, and obesity. Medications included furosemide, amlodipine, carvedilol, valsartan, insulin, canaglifozin, and atorvastatin. Surgical history was significant for appendectomy, rotator cuff surgery, and sinus surgery. His family history revealed multiple cancers in both maternal and paternal sides of his family. The patient was an active smoker with a 20 pack-year history. His exam in the of-

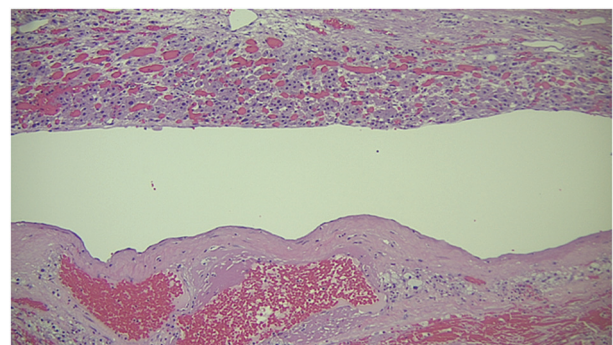


Figure 1. Papillary endothelial projections surrounding a thrombus.

Manuscript accepted for publication May 27, 2015

^aCharles E. Schmidt College of Medicine at Florida Atlantic University, Boca Raton, FL, USA

^bMiller School of Medicine at the University of Miami, Miami, FL, USA

^cCorresponding Author: David A. Levine, Charles E. Schmidt College of Medicine at Florida Atlantic University, Boca Raton, FL, USA.
Email: dlevine122@gmail.com

doi: <http://dx.doi.org/10.14740/jmc2127w>

findings were unremarkable for any focal findings.

The patient's hypertension had been poorly controlled with pharmacological therapy, and CT angiogram was performed to rule out renal artery stenosis. CT was negative for renal artery stenosis, but instead revealed a heterogeneous, 4.3 × 3.5 cm mass involving the left adrenal gland. The lesion measured 28 Hounsfield units (HU) and exhibited > 60% contrast washout; tests for adrenal adenoma, pheochromocytoma, and carcinoma were done as well. Urine metanephrines and catecholamines were normal, as well as sodium, potassium, aldosterone levels, and aldosterone/renin ratio, thus a period of watchful waiting was begun. On follow-up CT done 6 months later, the mass had grown to 7.0 × 5.8 cm, and the decision to excise the mass for pathology was reached. This patient successfully underwent a left adrenalectomy and pathological examination confirmed it to be Masson's tumor of the adrenal medulla.

Discussion

Intravascular papillary endothelial hyperplasia (Masson's Tumor) is extremely rare as an adrenal lesion and is more commonly seen superficially in the oral cavity, skin, head, neck, and extremities [1]. In this particular case, the incidental finding of an adrenal mass on imaging prompts an investigation into more common and serious etiologies. These included pheochromocytoma, adrenal adenoma, metastases, and carcinoma. Initially when evaluating an incidental adrenal gland mass, size is a major factor in management. Lesions < 4 cm with benign radiographic characteristics and which are not hormonally active may be followed with CT scan and laboratory testing [5]. Lesions measuring 4 to 6 cm can be watched if benign appearing, but should be excised if expected to be malignant or hormonally active. It is generally accepted that lesions > 6 cm should be excised. Due to the fact that our patient had a lesion that was slightly over the cutoff, but had benign features on CT, follow-up imaging in 3 - 6 months was the preferred course of action.

Radiologic imaging of adrenal masses yields a large amount of useful information. HU represent the amount of linear attenuation coefficient of X-rays as they pass through different tissues. Each tissue falls at a different value on the Hounsfield scale, distilled water being 0. Based on this measurement, one can discern what tissues comprise structures on CT. In terms of adrenal masses, HU are valuable in ruling out different etiologies. Adrenal adenomas (which are high in fat) attenuate to < 10 HU; this HU cutoff is 71% sensitive and 98% specific for adrenal adenoma [6]. Attenuation of 80 - 90 HU often denotes a benign lesion, and pheochromocytomas usually enhance beyond 100 HU. If there is any uncertainty, IV contrast washout should be done. Benign etiologies and adenomas usually have > 50% contrast washout, whereas pheochromocytoma, adrenocortical carcinoma, and metastases do not. Taking this into account, our patient's radiologic imaging that showed 28 HU and > 68% washout seemed to lean towards a benign etiology.

Biochemical testing on this patient represented a non-

functional mass. Testing for the common types of functional adrenal masses together with radiologic imaging will help guide a physician's clinical decision making. Pheochromocytoma, Cushing's syndrome, and aldosteronoma comprise the most common functional adrenal masses. Testing for each of these conditions is important in narrowing down the etiology of adrenal masses. If an adrenal mass is found to be hormonally non-active, follow-up with CT can be chosen as long as it meets the criteria for being less than 4 cm and has benign characteristics [5]. Lesions between 4 and 6 cm may be followed depending on clinical assessment by the physician as well as radiologic and laboratory testing.

Conclusion

The diagnostic assessment of an incidental adrenal lesion on imaging involves many malignant and benign diseases. It is important to rule out the common tumors before considering any other etiologies. Common lesions include cysts, carcinoma, and adenoma of the adrenal gland. Based on serological testing and radiographic studies, workup of these lesions includes either excision or watchful waiting. Though intravascular papillary endothelial hyperplasia represents an interesting and rare lesion of the adrenal gland, the proper steps of excluding more serious lesions must be taken before considering it as a diagnosis.

References

1. Akdur NC, Donmez M, Gozel S, Ustun H, Hucumenoglu S. Intravascular papillary endothelial hyperplasia: histomorphological and immunohistochemical features. *Diagn Pathol.* 2013;8:167.
2. Liu YY, Chiang PH. Adrenal Intravascular Papillary Endothelial Hyperplasia: A Case Report and Literature Review. *Urological Science.* 2013;24(4):129-130.
3. Makos CP, Nikolaidou AJ. Intravascular papillary endothelial hyperplasia (Masson's tumor) of the oral mucosa. Presentation of two cases and review. *Oral Oncology Extra.* 2004;40(4):59-62.
4. Witt P, Gault J, Kleinschmidt-DeMasters BK. Final Diagnosis - Masson's tumor (papillary endothelial hyperplasia). University of Pittsburgh Medical Center Department of Pathology. 2014.
5. Zeiger MA, Thompson GB, Duh QY, Hamrahian AH, Angelos P, Elaraj D, Fishman E, et al. American Association of Clinical Endocrinologists and American Association of Endocrine Surgeons Medical Guidelines for the Management of Adrenal Incidentalomas: executive summary of recommendations. *Endocr Pract.* 2009;15(5):450-453.
6. Willatt JM, Francis IR. Radiologic evaluation of incidentally discovered adrenal masses. *Am Fam Physician.* 2010;81(11):1361-1366.