

Primary *Nocardia farcinica* Brain Abscess With Secondary Relapsing Meningitis in an Immunocompromised Patient

Eleni Mylona^{a, b}, Styliani Golfinopoulou^a, Anthi Tragousti^a, Athanasios Skoutelis^a

Abstract

Nocardiosis is an opportunistic infection primarily affecting immunocompromised patients. Central nervous system (CNS) involvement in the form of cerebral abscesses may be a complication of nocardia infection. *Nocardia farcinica*, in particular, is believed to disseminate the CNS more often than other nocardia species, being associated with antibiotic resistance and therefore higher mortality. We describe the first case of a patient with relapsing meningitis caused by *N. farcinica*. A 61-year-old Caucasian man was admitted for evaluation of fever, headache and confusion. Magnetic resonance imaging of the brain revealed cerebral abscesses and examination of the cerebrospinal fluid (CSF), polymorphonuclear count, elevated protein and hypoglycorrhachia. CSF cultures were negative, while multiplex polymerase chain reaction showed *Staphylococcus aureus*. The patient received vancomycin/meropenem and later, because he was still febrile, with symptoms from the CNS, linezolid/meropenem, in which he responded well. During the following months, he had to discontinue linezolid because of myelosuppression with subsequent relapses of meningitis. In such a relapse, the patient was admitted for reevaluation. CNS cultures grew *N. farcinica*, susceptible to linezolid, trimethoprim/sulfamethoxazol and ceftriaxone. He was discharged on trimethoprim/sulfamethoxazole for 12 months. This is the first reported case of relapsing meningitis caused by *N. farcinica*. It highlights, on the one hand, the importance of the prolonged treatment in relapse's prevention and on the other, the limited value of linezolid as prolonged treatment due to its long-term toxicities.

Keywords: *Nocardia farcinica*; Brain abscess; Meningitis; Relapse; Linezolid

Introduction

Nocardiosis is a localized or disseminated infection caused by a soil-borne, aerobic actinomycete [1]. There are at least 50 recognized species of the genus *Nocardia*, with *N. asteroides* to be the predominant one. *Nocardia farcinica* has recently been redefined as a separate species, distinct from *N. asteroides* [2]. The portals of entry of *Nocardia* spp. are the respiratory tract and surgical or traumatic skin wounds. Central nervous system (CNS) involvement is a well-described complication of nocardia infection. Most cases of CNS disease are considered as a disseminated infection from a lung focus [3].

The majority of the affected patients are immunocompromised, usually because of prolonged treatment with systemic corticosteroids treatment, HIV infection, solid organ transplantation, malignancy or diabetes mellitus [1]. Delayed diagnosis is common because *Nocardia* spp. grow slowly or are non-cultivable [4].

We describe the first case of patient with relapsing meningitis caused by *N. farcinica*.

Case Report

A 61-year-old man was admitted to our department for evaluation of fever, headache and confusion. His past medical history included autoimmune hemolytic anemia 1 year ago treated with methylprednisolone for 3 months.

The patient had a long story of present illness before current admission. Seven months before he had been admitted to another hospital with fever and confusion. Gadolinium-enhanced magnetic resonance imaging (MRI) of the brain had revealed a multilobular, peripheral-enhancing mass on the rim of the left lateral ventricle, consistent with a row of cerebral abscesses (Fig. 1). Examination of the cerebrospinal fluid (CSF) showed 216 WBCs/mm³ (65% neutrophils), a glucose level of 81 mg/dL and a protein level of 96 mg/dL. CSF cultures for bacteria, mycobacteria, fungi and nocardia were negative and the patient was started on ceftriaxone, vancomycin and metronidazole. CSF analysis using multiplex polymerase chain reaction (PCR) revealed *Staphylococcus aureus*. Treatment was changed to vancomycin and meropenem.

Fifteen days later the patient was still febrile and a new brain MRI showed almost complete resolution of the ring-enhanced lesions (Fig. 2). However, the repeat lumbar puncture revealed

Manuscript accepted for publication April 16, 2015

^aThe 5th Department of Medicine and Infectious Diseases, Evangelismos Hospital, Athens, Greece

^bCorresponding Author: Eleni Mylona, The 5th Department of Internal Medicine, Evangelismos Hospital, 45-47 Hipsilantou St, Kolonaki, GR-10676, Athens, Greece. Email: emylon@med.uoa.gr

doi: <http://dx.doi.org/10.14740/jmc2157w>

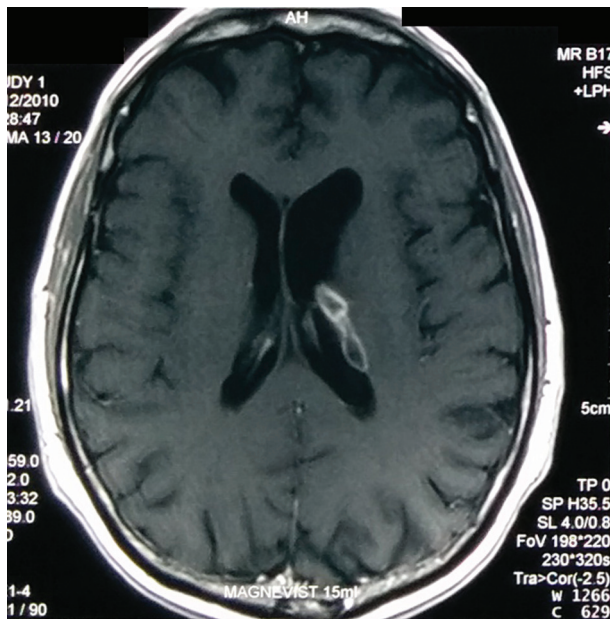

Figure 1. Gadolinium-enhanced MRI of the brain (during the patient's previous admission) had revealed a multilobular, peripheral-enhancing mass on the rim of the left lateral ventricle, consistent with a row of cerebral abscesses.

higher polymorphonuclear count, elevation of CSF protein and hypoglycorrhachia. On the basis of these findings, the treatment was changed to linezolid and meropenem. The patient became afebrile from the fourth day of linezolid's infusion. After 3 months, he was discharged home afebrile, without symptoms from the CNS, on linezolid. During the following 4 months, linezolid had to be discontinued for several weeks because of myelosuppression with subsequent relapses of the fever and headache. Because of the recurrence, the patient was admitted to our department.

During current admission, the patient had fever and headache. He was febrile but not confused or lethargic and he had nuchal rigidity, without other meningeal or focal neurological signs. Routine laboratory examination, chest radiograph and brain computed tomography (CT) scan were normal. CSF showed 1,220 WBCs/mm³ (80% neutrophils), protein 267 mg/dL and glucose 30 mg/dL. Linezolid was initiated.

On day 5 of hospitalization, CNS cultures grew branching, gram positive bacteria that were later identified as *N. farcinica*. The organism was susceptible to amikacin (1.5 µg/mL), imipenem (1 µg/mL), trimethoprim/sulfamethoxazole (TMP/SMX) (2 µg/mL), linezolid (0.25 µg/mL) and ciprofloxacin (0.75 µg/mL) while the susceptibility to ceftriaxone was intermediate (16 µg/mL). Treatment was changed to TMP/SMX and high doses of ceftriaxone.

After 3 weeks, the patient was significantly improved and discharged from the hospital on TMP/SMX for 12 months.

Discussion

Nocardiosis is usually an opportunistic infection that occurs

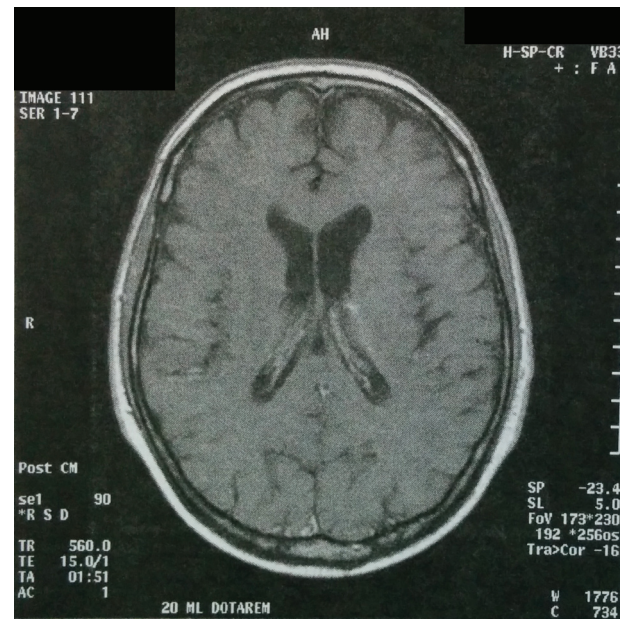


Figure 2. After 15 days on vancomycin/meropenem, a new brain MRI showed almost complete resolution of the ring-enhanced lesions.

most often in immunosuppressed patients. *Nocardia* spp. cerebral abscesses are rare, accounting for 2% of all CNS abscesses [5]. They usually occur as part of a disseminated pulmonary or cutaneous disease [1]. However, in one-third of the cases, cerebral abscess occurs as an isolated lesion without evidence of extracranial disease [6]. Clinical manifestations of CNS involvement come from local effects of the abscess, usually appearing as multiple enhancing lesions on CT and occasionally accompanied by meningitis [7]. Our patient presented with cerebral abscess accompanied by meningitis, without extracranial disease. *Nocardia* spp. are difficult to culture, grow slowly and their growth may be contaminated by faster growing species, delaying the start of the appropriate antibiotic treatment [4, 7]. Prolonged course of oral antimicrobials (> 12 months) is considered necessary to prevent relapses [8].

N. farcinica has recently been identified as a separate species distinct from *N. asteroides* [2]. Based on experimental [9] and clinical data [4], *N. farcinica* is believed to disseminate the CNS more often than other nocardia species, being associated with higher mortality. Furthermore, *N. farcinica* is more often associated with antibiotic resistance, especially in third generation cephalosporins which are commonly used as empiric antimicrobial therapy in cases of brain abscess [2]. Recently, linezolid has been successfully used for the treatment of *N. farcinica* infection [10].

Our patient presented several diagnostic and therapeutic challenges. On his initial admission nocardia failed to be isolated from the CSF cultures, leading to the start of ceftriaxone, vancomycin and metronidazole in which *N. farcinica* was resistant. The diagnosis was further complicated by contamination with *S. aureus* which caused the switch of the treatment to vancomycin, meropenem, without clinical improvement, despite the resolution of the abscess in brain MRI. Fortunately, vancomycin was changed to linezolid, later shown to have adequate activity

against the infecting strain of *N. farcinica*. Therapy with linezolid had to be interrupted several times leading to prompt relapses.

Conclusion

To the best of our knowledge, this is the first reported case of relapsing meningitis caused by *N. farcinica*. It highlights, on the one hand, the importance of the prolonged treatment in relapse's prevention and on the other, the limited value of linezolid as prolonged treatment due to its long-term toxicities.

Conflict of Interest

The authors state no conflict of interest.

References

1. Saubolle MA, Sussland D. Nocardiosis: review of clinical and laboratory experience. *J Clin Microbiol.* 2003;41(10):4497-4501.
2. Wallace RJ, Jr., Tsukamura M, Brown BA, Brown J, Steingrube VA, Zhang YS, Nash DR. Cefotaxime-resistant *Nocardia asteroides* strains are isolates of the controversial species *Nocardia farcinica*. *J Clin Microbiol.* 1990;28(12):2726-2732.
3. Kilincer C, Hamamcioglu MK, Simsek O, Hicdonmez T, Aydoslu B, Tansel O, Tiryaki M, et al. Nocardial brain abscess: review of clinical management. *J Clin Neurosci.* 2006;13(4):481-485.
4. Torres OH, Domingo P, Pericas R, Boiron P, Montiel JA, Vazquez G. Infection caused by *Nocardia farcinica*: case report and review. *Eur J Clin Microbiol Infect Dis.* 2000;19(3):205-212.
5. Mathisen GE, Johnson JP. Brain abscess. *Clin Infect Dis.* 1997;25(4):763-779; quiz 780-761.
6. Mamelak AN, Obana WG, Flaherty JF, Rosenblum ML. Nocardial brain abscess: treatment strategies and factors influencing outcome. *Neurosurgery.* 1994;35(4):622-631.
7. Kumar VA, Augustine D, Panikar D, Nandakumar A, Dinesh KR, Karim S, Philip R. *Nocardia farcinica* brain abscess: epidemiology, pathophysiology, and literature review. *Surg Infect (Larchmt).* 2014;15(5):640-646.
8. Hitti W, Wolff M. Two cases of multidrug-resistant *Nocardia farcinica* infection in immunosuppressed patients and implications for empiric therapy. *Eur J Clin Microbiol Infect Dis.* 2005;24(2):142-144.
9. Jodlowski TZ, Melnychuk I, Conry J. Linezolid for the treatment of *Nocardia* spp. infections. *Ann Pharmacother.* 2007;41(10):1694-1699.
10. Desmond EP, Flores M. Mouse pathogenicity studies of *Nocardia asteroides* complex species and clinical correlation with human isolates. *FEMS Microbiol Lett.* 1993;110(3):281-284.