

Life-Threatening Intracranial Hemorrhage With Unexpectedly High Prothrombin Time Following Venous Thromboembolism Prophylaxis

Hassan Tahir^{a, b}, Adil Wani^a, Vistasp Daruwalla^a

Abstract

Effective thromboprophylaxis with low-dose subcutaneous heparin has been shown to reduce morbidity and mortality. Low-dose prophylactic heparin usually has very low bleeding risk and therefore, prothrombin time (PTT) monitoring or dose adjustment according to age, weight and renal function is not recommended. Life-threatening hemorrhage and markedly elevated PTT with prophylactic heparin is a very rare complication. An 86-year-old woman was admitted with urinary tract infection (UTI) and started on 5,000 U subcutaneous heparin three times a day. Patient condition improved but on day 3, she developed sudden onset of headache, confusion and drowsiness. CT of head showed massive intracranial bleed with midline shift. Craniotomy was done and hematoma was evacuated. PT/INR was normal but PTT was significantly prolonged. Rest of laboratory investigations were inconclusive which ruled out other important causes of elevated PTT and bleeding. Patient was given protamine sulphate and transfused fresh frozen plasma, packed red blood cells and platelets. Patient condition deteriorated and family decided to withdraw life support. Venous thromboembolism (VTE) prophylaxis may be complicated by hemorrhage especially in high risk patients. Heparin should be used cautiously and its effect should be monitored in such patients. Though low-dose unfractionated heparin thrice daily has been found to be superior to twice daily heparin in preventing thromboembolism, bleeding risk is higher.

Keywords: Intracranial hemorrhage; Prolonged PTT; Venous thromboembolism; Low molecular weight heparin; Unfractionated heparin; VTE prophylaxis

Introduction

Venous thromboembolism (VTE) is the collective term used

for deep vein thrombosis (DVT) and pulmonary embolism (PE), which is the leading cause of significant morbidity and mortality in hospitalized patients with approximately 200,000 deaths each year from PE alone in US hospitals [1]. Low-dose unfractionated heparin (LD-UFH) or low molecular weight heparin (LMWH) is commonly used for VTE prophylaxis and has been shown in various studies to reduce the risk of thromboembolism. LD-UFH or LMWH does not cause significant prothrombin time (PTT) prolongation, hence regular PTT monitoring is not recommended [2]. Life-threatening hemorrhage with low-dose subcutaneous heparin secondary to markedly high PTT is a very rare complication. We report a case of abnormally high PTT in an old lady who developed massive intracranial hemorrhage after LD-UFH.

Case Report

An 86-year-old woman presented to emergency department (ED) with generalized weakness. She was recently diagnosed with urinary tract infection (UTI) which grew enterococcus on culture, and she was started on nitrofurantoin. Patient was unable to tolerate antibiotic and developed nausea, vomiting and diarrhea. According to patient's family, she had been having off and on episodes of confusion and forgetfulness for last few months for which outpatient CT of head was done recently which did not show any acute changes (Fig. 1). It was thought that her UTI might be contributing to her waxing and waning altered mental state. Patient was unable to complete course of nitrofurantoin and presented to ED with generalized weakness and letharginess. Patient denied any fever, chills, cough, shortness of breath or chest pain.

She did not have any headache, neck pain or photophobia. Patient also denied any frequency, urgency, dysuria or burning micturation. She did have some light headedness which started after multiple episodes of vomiting and diarrhea. Patient used to live with her husband and was able to perform activities of daily living. Past medical history was significant for hypertension, cervical adenocarcinoma, hypothyroidism, osteoarthritis, stress incontinence, aortic stenosis and venous insufficiency. Her home medications included baby aspirin, lisinopril, bumetanide, iron and multivitamins.

Patient was hypotensive with systolic blood pressure in 80s when she was brought to the emergency. Rest of the vitals

Manuscript accepted for publication May 20, 2015

^aDepartment of Internal Medicine, Temple University/Conemaugh Memorial Hospital, 1086 Franklin Street, Johnstown, PA 15905, USA

^bCorresponding Author: Hassan Tahir, Department of Internal Medicine, Temple University/Conemaugh Memorial Hospital, 1086 Franklin Street, Johnstown, PA 15905, USA. Email: htahir@conemaugh.org

doi: <http://dx.doi.org/10.14740/jmc2193w>

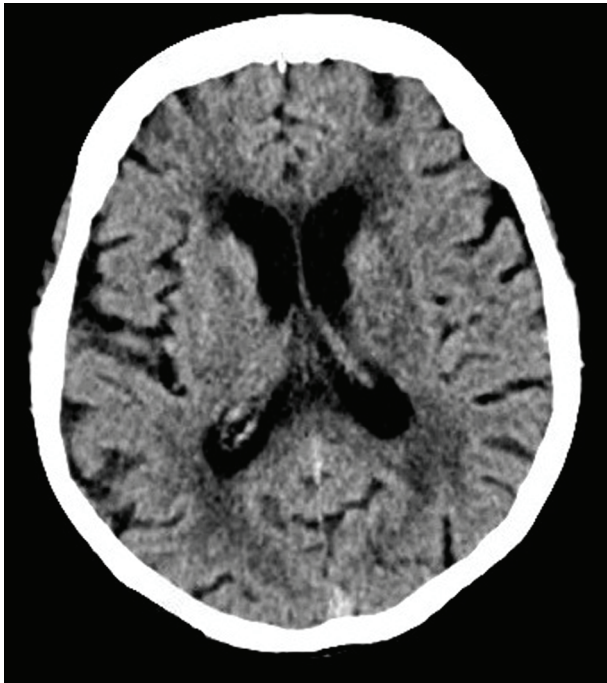

Figure 1. CT of head done 1 week before admission showing no hemorrhage.

were stable. Urine analysis showed too numerous WBCs. Patient was given 2 L of normal saline bolus and 1 g of rocephin intravenously. Patient's blood pressure improved significantly after fluid resuscitation. She was admitted in the hospital on the suspicion of possible sepsis secondary to UTI. Urine culture was again positive for enterococcus which was sensitive to penicillins. Blood and sputum cultures were negative for any bacteria. All baseline tests including CBC, CXR, EKG, serum electrolytes, renal and liver function were normal at the time of admission other than albumin level which was low (2.1 g/dL). PT/INR and PTT were also within normal limits. Patient was continued on rocephin and most of her home medications including baby aspirin. Patient was started on subcutane-

ous 5,000 U unfractionated heparin three times a day for VTE prophylaxis.

Patient condition improved during the hospital stay and she was about to be discharged, when on day 3, she started complaining of severe headache and subsequently became acutely confused, lethargic and obtunded. Her blood pressure was slightly high. A stat CT was obtained which showed bilateral acute extra-axial hemorrhage, right significantly greater than left, with severe mass effect in the right cerebral hemisphere and midline shift (Fig. 2). Patient was intubated and immediately transferred to ICU. Patient was seen by neurosurgery that performed craniotomy and drainage of large right acute subdural hematoma. A Jackson-Pratt drain (JP drain) was placed to allow drainage of any accumulated blood. Repeat laboratory investigations showed normal PT/INR but PTT was elevated to > 100 (Table 1). Taking into account possible laboratory error, PTT was repeated again which again came back more than 100. Aspirin and subcutaneous heparin was immediately discontinued. D dimer, fibrinogen and CBC were normal and peripheral smear did not show any abnormal RBC morphology. Similarly, liver functions and renal functions were normal. Normal PTT at the time of admission with markedly high PTT after starting subcutaneous heparin in the presence of negative DIC panel led to the diagnosis of heparin-induced intracranial hemorrhage. Patient was given protamine sulfate and transfused 2 units of fresh frozen plasma (FFP). PPT was repeated after 3 h which showed significant fall in PTT (Table 1). In the mean time, patient's hemoglobin also dropped to 8.6. Two units of packed red blood cell (PRBC), one more unit of FFP and one unit of platelets were transfused. Repeat CT scan of head done next day showed persistent extra-axial hematoma and severe parafalcine herniation much worse as compared to previous scan (Fig. 3). Taking into account the deteriorating condition of patient and poor prognosis, family decided to withdraw life support and continue only end of life care.

Discussion

DVT is defined by the formation of thrombus with in deep

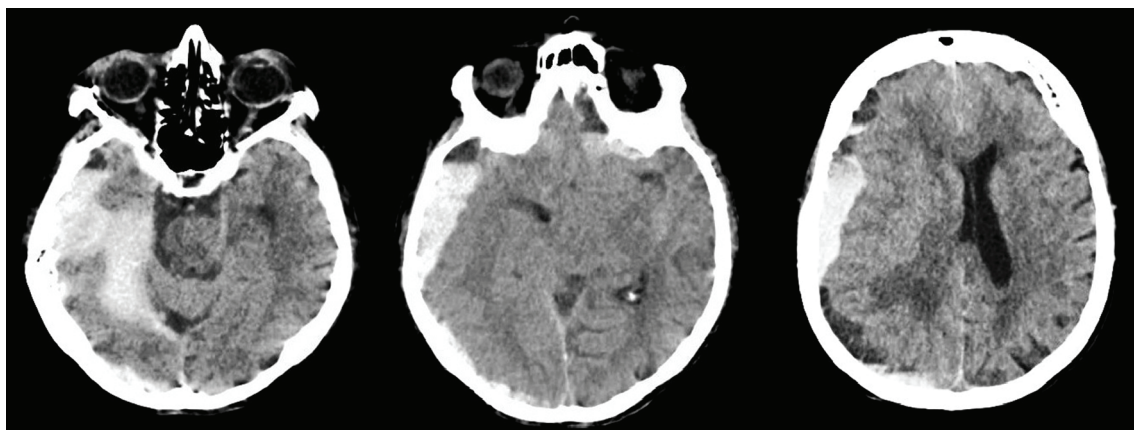


Figure 2. Large right extra-axial hemorrhage with midline shift and small hemorrhage in left frontal region. There is also mild bilateral subarachnoid hemorrhage.

Table 1. Laboratory Investigations From Day of Admission

Labs	On admission	3 days later	4 days later
Hemoglobin	12	10	8.9
WBC	3.5	3.6	7.0
Platelets	172	168	196
PT/INR	10.6/1.0	10.4/1.0	10.4/1.0
PTT	29	> 100. Repeat PTT was again > 100. PTT was 83 after 1 unit of FFP.	53

veins of legs that may extend higher into pelvic veins. Clot in deep veins may dislodge and migrate to lungs where they can impede blood flow in pulmonary artery or its branches leading to a life-threatening condition called PE. The close association between DVT and PE led to the use of term “VTE” that covers both conditions. There are a number of risk factors for developing VTE, the most common being the old age, previous DVT, immobility, cancer, acute infection, surgery and pregnancy [3]. Old age is an independent risk factor for VTE, which along with immobilization and co-morbid medical conditions may strikingly increase the risk of DVT, thus stressing the need of adequate thromboprophylaxis in critically ill old patients [4].

Pharmacological VTE prophylaxis should be started in all high risk patients after risk assessment. American College of Chest Physicians (ACCP) recommends LD-UFH or LMWH for patients with high risk of VTE [5]. Unfractionated heparin is a complex mixture of glycosaminoglycans which binds to antithrombin III to form a complex which in turn inactivates factor IIa (thrombin) and factor Xa [2]. Inhibition of thrombin causes elevation of PTT and that is the reason PTT levels are used to monitor therapeutic unfractionated heparin therapy. But in case of subcutaneous LD-UFH for VTE prophylaxis, PTT elevation is very mild and risk of bleeding is low, thus regular PTT monitoring is not recommended. PTT is a performance indicator of the efficacy of both the intrinsic and the common coagulation pathways. The most common causes of prolonged PTT are therapeutic heparin therapy, liver disease, DIC, factor inhibitors and inherited or acquired factor deficiencies. The PTT may not be prolonged until the factor levels have decreased to 30-40% of normal and that is why

low-dose subcutaneous heparin does not lead to significant prolongation of PTT as it does not produce sufficient blood levels to significantly decrease coagulation factors. Heparin has a shorter half life and has variable and extensive binding to plasma proteins and reticuloendothelial system (RES), thus producing a variable response. RES plays an important role in the clearance of unfractionated heparin. On the other hand, LMWH is formed by the fractionation of heparin molecules with less protein binding, dose-independent clearance and better bioavailability. These features produce a longer half life and make anticoagulant response of LMWH more predictable. LMWH interacts less readily with platelet factor 4, decreasing the risk of heparin-induced thrombocytopenia, a complication of some patients receiving heparin therapy [6]. LMWH has more effect on inhibiting factor Xa and hence does not increase PTT at therapeutic doses. Once daily dosing and more predictable anticoagulation affect makes it the pharmacological VTE prophylaxis of choice for many physicians. LMWH is cleared by kidneys and therefore it is not recommended in patients with kidney disease, thus making LD-UFH as the only choice in such cases.

Both unfractionated heparin and LMWH have been shown to reduce the risk of VTE but recent data suggest that LMWH might be slightly more effective in reducing thrombosis as compared to unfractionated heparin with same risk of bleeding [7]. In addition, a meta-analysis of randomized controlled trials suggested that LMWH might have better safety profile with less risk of bleeding [8]. Unfractionated heparin, on the other hand, can produce variable and unpredictable effects depending on its bioavailability and clearance. Thrice daily dosing vs.

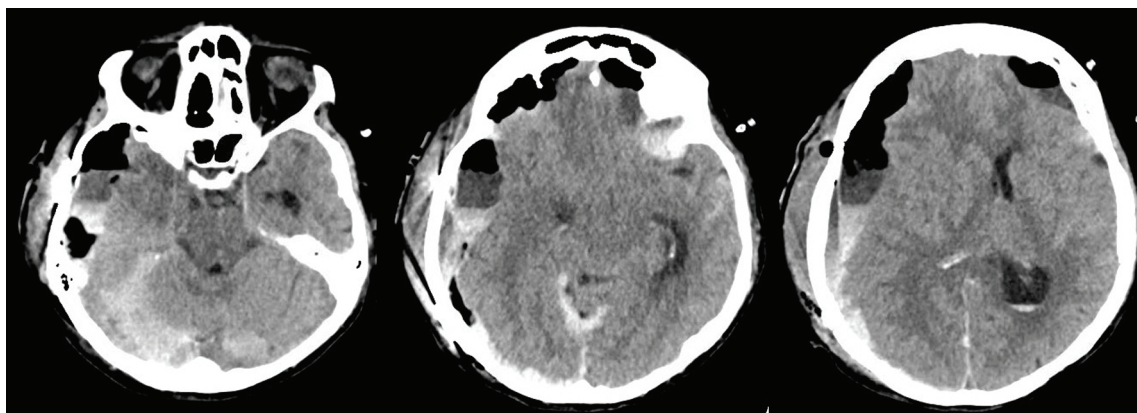


Figure 3. Post-surgical CT of head showing persistent acute on chronic extra-axial hematoma. There is increase in the size of left frontal lobe hematoma. Note severe parafalcine herniation much worse than the previous CT scan.

twice daily dosing of unfractionated heparin has always been a topic of hot debate. Most recent ACCP guidelines recommend using LD-UFH without specifying frequency or dose. Various studies and meta-analysis have been done to compare efficacy and bleeding risk between twice and thrice daily heparin dose. A meta-analysis of 12 randomized controlled studies concluded that thrice daily LD-UFH appeared to be superior to twice daily heparin in preventing thromboembolism; however, bleeding risk was higher [9]. Therefore, risk vs. benefit should always be taken into account and heparin frequency decided accordingly. Heparin 5,000 U twice a day may be a better option for those who are at increased risk of bleeding.

Significant bleeding with very high PTT following VTE prophylaxis is a very rare complication. Elevated PTTs during LD-UFH have been reported previously [10, 11]. But life-threatening intracranial hemorrhage with markedly high PTT after low-dose heparin prophylaxis has not been recognized before. A number of factors can increase and prolong heparin action resulting in significant elevation of PTT following low-dose heparin VTE prophylaxis, thus increasing the risk of bleeding. These factors include old age, low weight, low plasma proteins and abnormal liver and renal functions [2]. In one study, longer PTTs were associated with < 70 kg weight, age > 65 years, female sex, and black race; shorter PTTs were associated with diabetes and smoking [12]. Risk of bleeding is more with unfractionated heparin due to its unpredictable and variable anticoagulation response. In patients with above risk factors, heparin 5,000 U twice a day or LMWH might be a better option.

Our patient presented with UTI and was considered at very high risk for VTE due to old age, infection, immobility and malignancy. She was started on 5,000 U subcutaneous unfractionated heparin three times a day. On day 3, patient developed massive intracranial hemorrhage with midline shift. The most noticeable laboratory finding was significantly prolonged PTT. Our differential diagnosis included heparin overdose, DIC, liver disease, lupus anticoagulant and coagulation factor deficiencies. Extensive workup was done to rule out each differential diagnosis. Patient's PTT was normal on admission and she did not have any bleeding tendency in past, so inherited disorders were ruled out. Thrombin time (TT) was prolonged and reptilase time (RT) was normal. Mixing studies did not show any factor inhibitors. DIC was a likely possibility because patient had UTI. Blood cultures were negative and laboratory tests were inconclusive with normal platelets, fibrinogen, D dimers and peripheral blood smear. Rest of lab tests including liver, renal function tests and lupus anticoagulant were normal. Results of above tests and elevated PTT after starting subcutaneous heparin further reinforced our suspicion of heparin overdose as the cause of bleeding. The patient was not on any NSAIDs or blood thinners before admission to hospital. All nursing notes and doctor's orders were reviewed to find out the triggering factor for heparin overdose. Saline not the heparin flushes were used to clear intravenous and central lines. No mistake was found on the part of nurses regarding dose miscalculation or accidentally administering heparin intravenously instead of subcutaneously. Laboratory error was a possibility and every effort was made to find out any possible error. Accurate sample collection, handling, transportation, processing and

storage were done, thus minimizing pre-analytical laboratory error. Similarly, analytical errors were avoided by using appropriate test methodologies and by incorporation of appropriate control measures. Still PTT was repeated to rule out any laboratory error which came back again very high. Patient history was carefully reviewed to find out anything unusual that might be contributing to heparin overdose. As unfractionated heparin was used, it is already known to have variable and unpredictable effects as compared to LMWH. Old age, low albumin, aging reticuloendothelial system and low weight were the factors in our patient which might have contributed to decreased clearance of LD-UFH. In addition, thrice daily dosing was used as VTE prophylaxis which in recent studies has been shown to increase bleeding risk especially in old patients. Patient was also on baby aspirin which also increased the bleeding risk. We believe that delayed clearance of LD-UFH was the main factor responsible for life-threatening bleeding in our patient.

Conclusion

The purpose of this case report is not to discourage medical practitioners from VTE prophylaxis as effective thromboprophylaxis can safely reduce the incidence of VTE decreasing the morbidity and mortality. In fact, our sole purpose is to warn doctors about the possibility of life-threatening hemorrhage with low-dose subcutaneous heparin. Very old people, on one hand, are at increased risk of DVT, but, on the other hand, they are also at increased risk of bleeding especially those having comorbid conditions. PTT monitoring is not recommended with VTE prophylaxis, but it should be considered in selected high risk patients especially very old (> 80 years). If kidney functions are normal, LMWH could be a better choice due to its more predictable effect and low risk of bleeding. But if LD-UFH is started, heparin twice daily instead of thrice daily might be a safe option in such high risk patients. Further studies are needed to evaluate the dose and type of pharmacologic thromboprophylaxis in special patient populations. The prophylactic use of heparin can become safer if appropriately used, effect is monitored and its pharmacokinetics is considered.

Competing Interests

Authors confirm that they have no competing interests.

Abbreviations

VTE: venous thromboembolism; DVT: deep vein thrombosis; PE: pulmonary embolism; LD-UFH: low-dose unfractionated heparin; LMWH: low molecular weight heparin; PTT: prothrombin time

References

1. Geerts WH, Pineo GF, Heit JA, Bergqvist D, Lassen MR,

- Colwell CW, Ray JG. Prevention of venous thromboembolism: the Seventh ACCP Conference on Antithrombotic and Thrombolytic Therapy. *Chest*. 2004;126(3 Suppl):338S-400S.
2. Hirsh J, Dalen JE, Deykin D, Poller L. Heparin: mechanism of action, pharmacokinetics, dosing considerations, monitoring, efficacy, and safety. *Chest*. 1992;102(4 Suppl):337S-351S.
 3. Anderson FA, Jr., Spencer FA. Risk factors for venous thromboembolism. *Circulation*. 2003;107(23 Suppl 1):I9-16.
 4. Ageno W, Agnelli G, Imberti D, Moia M, Palareti G, Pistelli R, Rossi R, et al. Risk factors for venous thromboembolism in the elderly: results of the master registry. *Blood Coagul Fibrinolysis*. 2008;19(7):663-667.
 5. Geerts WH, Bergqvist D, Pineo GF, Heit JA, Samama CM, Lassen MR, Colwell CW. Prevention of venous thromboembolism: American College of Chest Physicians Evidence-Based Clinical Practice Guidelines (8th Edition). *Chest*. 2008;133(6 Suppl):381S-453S.
 6. Warkentin TE, Levine MN, Hirsh J, Horsewood P, Roberts RS, Gent M, Kelton JG. Heparin-induced thrombocytopenia in patients treated with low-molecular-weight heparin or unfractionated heparin. *N Engl J Med*. 1995;332(20):1330-1335.
 7. Wein L, Wein S, Haas SJ, Shaw J, Krum H. Pharmacological venous thromboembolism prophylaxis in hospitalized medical patients: a meta-analysis of randomized controlled trials. *Arch Intern Med*. 2007;167(14):1476-1486.
 8. Mismetti P, Laporte-Simitsidis S, Tardy B, Cucherat M, Buchmuller A, Juillard-Delsart D, Decousus H. Prevention of venous thromboembolism in internal medicine with unfractionated or low-molecular-weight heparins: a meta-analysis of randomised clinical trials. *Thromb Haemost*. 2000;83(1):14-19.
 9. King CS, Holley AB, Jackson JL, Shorr AF, Moores LK. Twice vs three times daily heparin dosing for thromboembolism prophylaxis in the general medical population: A metaanalysis. *Chest*. 2007;131(2):507-516.
 10. Fiebig EW, Jones M, Logan A, Wang CS, Lewis B. Unexpectedly high PTT values after low-dose heparin prophylaxis. *Arch Intern Med*. 2011;171(7):702-703.
 11. Hudcova J, Talmor D. Life-threatening hemorrhage following subcutaneous heparin therapy. *Ther Clin Risk Manag*. 2009;5(1):51-54.
 12. Lee MS, Wali AU, Menon V, Berkowitz SD, Thompson TD, Califf RM, Topol EJ, et al. The determinants of activated partial thromboplastin time, relation of activated partial thromboplastin time to clinical outcomes, and optimal dosing regimens for heparin treated patients with acute coronary syndromes: a review of GUSTO-IIb. *J Thromb Thrombolysis*. 2002;14(2):91-101.