

# Wide Resection of Sacral Chordoma Including Gluteus Maximus Muscles via Posterior Approach

Burak Akesen<sup>a</sup>, Armagan Can Ulusaloglu<sup>a, b</sup>

## Abstract

Malign sacral tumors are treated by total sacrectomy and wide resection of soft tissue to reduce local recurrence and for cure. A 78-year-old male presented with low back pain and tenesmus. MRI showed a large tumor in sacrum and the biopsy result showed it was chordoma. "S" shaped incision was applied between L3 and Co2 and chordoma was taken out and gluteal maximus muscles were totally excised. General surgery opened the colostomy and plastic surgery was applied for the flap reconstruction after wound dehiscence. Total sacrectomy is a complicated and difficult surgery because of complex pelvic anatomy. Only posterior approach provides to come through the sacral tumors without anterior approach "laparotomy".

**Keywords:** Total sacrectomy; Gluteus; Chordoma

## Introduction

Among all bone tumors, primary sacrum tumors account for 1-4.3% [1, 2]. The most common primary malignant sacrum tumor is chordoma (50%) [1-3], which is the fourth malignant neoplasm originating from bone and has an incidence of less than 0.1 per 100,000 people per year [4].

Radical resection and reconstruction are the best therapies for malign sacrum tumors. In many cases, total or partial sacrectomy is necessary for cure. Surgical treatment, namely the total sacrectomy, is difficult because of the complex pelvis and sacrum anatomy and their relation with the surrounding tissues. In addition, after the resection, large cavity leads to wound problems which are potentially difficult to manage. A multidisciplinary approach is often necessary for these procedures, especially in collaboration with plastic surgery, which is

required for complex wound closures and flap reconstructions.

The diagnosis is mostly delayed due to slow growing of chordoma and vague symptoms. Total *en bloc* sacrectomy is a choice of treatment to achieve negative surgical margin and prevention of recurrence [5]. Sacral nerve preserving is valuable for quality of life in terms of bowel function, bladder function and sexual function, especially S2-S3 dermatomes. Therefore, surgical risks and postoperative aspects are explained to patients.

## Case Report

The patient, a 78-year-old male, presented with back pain and tenesmus. Neurological examination was significant with bowel and bladder dysfunction (incontinence), and loss of sensorial function through S2 and S4 dermatomes. Motor functions of lower extremities were normal. Rectal examination demonstrated empty ampulla recti.

Lumbosacral magnetic resonance imaging (MRI) showed all sacrum and coccyx segments were infiltrated. Expanded mass spread gluteal muscles especially "gluteus maximus" and perirectal fat tissue and posterior rectal walls. Tumor was measured 18 × 15 × 9 cm (Fig. 1, 2). Metastases were not observed in oncologic PET and bone scintigraphy. Histologic examination showed the chordoma after needle biopsy from S3 vertebra.

"S" shaped incision was done between L3 and Co 2 to reach gluteal muscle easily. We tried to preserve all nerves root but bilateral S2 and S3 roots were completely infiltrated inside tumor. Roots were sacrificed and right gluteal maximus muscles were totally excised.

As reconstruction, total sacrum was removed from ilium by cutting jigsaw from sacroiliac joint. Excised tumor was measured 30 × 19 × 8 cm (Fig. 3, 4).

General surgery opened the colostomy because rectum was infiltrated perioperatively. Wound closure was sutured primarily and made self-suctioning by three hemovac drains.

Ten days postoperatively, dehiscence occurred and vacuum dressing was applied for open wound after surgical debridement. Plastic surgery was implemented on gluteal muscles flap to close the wound after second surgical debridement.

Two months postoperatively, the patient was mobilized by assisted device. Urine and gaita incontinence was kept.

Manuscript accepted for publication August 13, 2015

<sup>a</sup>Uludag University Medical School Orthopedic and Traumatology Department, Turkey

<sup>b</sup>Corresponding Author: Armagan Can Ulusaloglu, Uludag University Medical School Orthopedic and Traumatology Department, Turkey.  
Email: canulusaloglu@gmail.com

doi: <http://dx.doi.org/10.14740/jmc2254w>

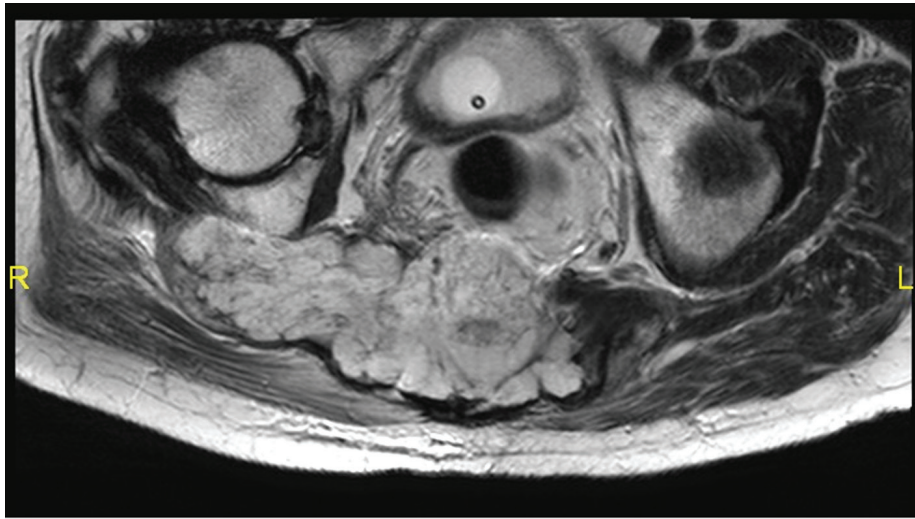


Figure 1. Invasion of gluteus maximus muscle.

**Discussion**

Primary sacral tumors are difficult to diagnose because of slight growth and show no local sign or systemic symptom. Intralesional or marginal surgical procedures increase local recurrence risk and complications of second surgery. Mostly radical resection procedures are applied for expanded and destructive malign tumors. Total *en bloc* sacrectomy with reconstruction caused structural and neurological damage, and sexual disturbances [6, 7].

Fuchs et al [8] showed no significant difference in long-term survival between posterior (n = 30) and combined anterior-posterior (n = 22) by following 52 patients. In this case report, only posterior approach was applied because of surgeon experience, age, wound closure and prolonged operation time.

Chen et al [5] followed 36 sacrectomy patients who have an average disease-free survival of 52 months with chordomas without muscular invasion, but 21 months with chordomas with muscular invasion. In our case, unilateral gluteus maxi-

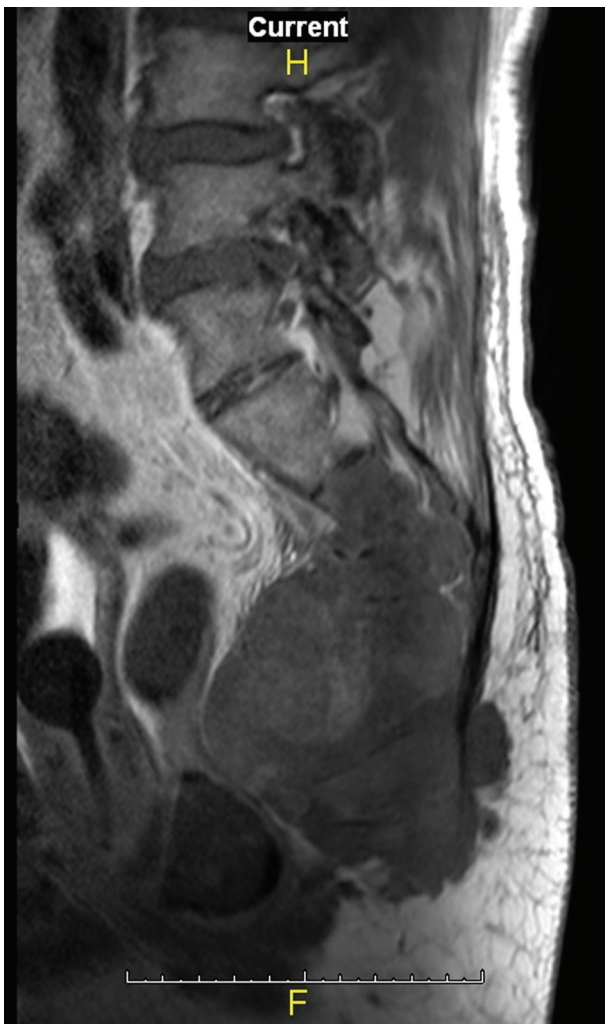
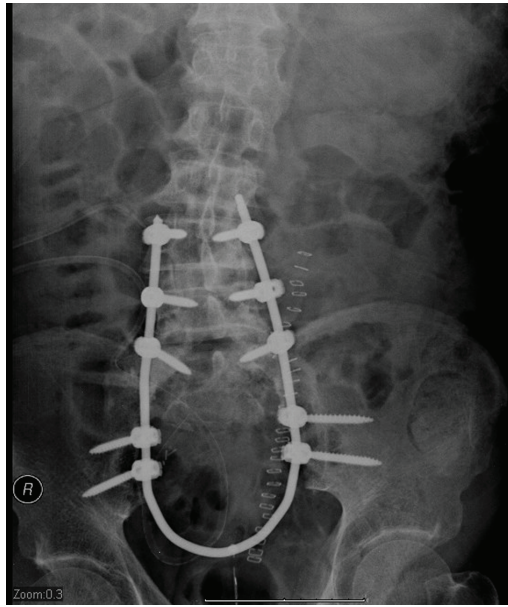


Figure 2. Perirectal invasion.

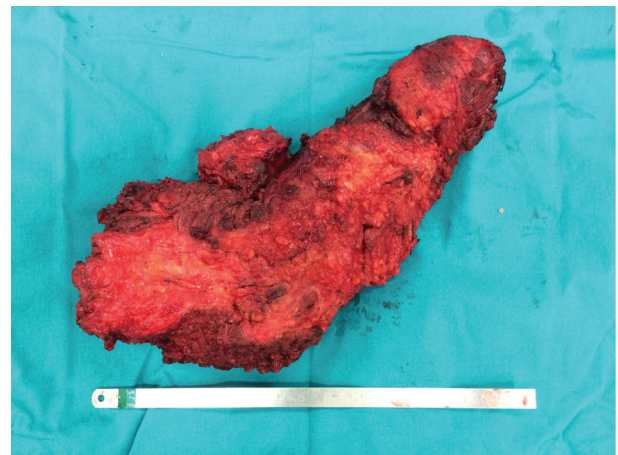

Figure 3. Excised tumor.



**Figure 4.** Reconstruction by "U" shaped rod.

mus muscle was totally excised, therefore survival rate and quality of life are restricted.

Ruggieri et al [9] found 74% polymicrobial infection in 23 sacrectomy patients. The most common agent was gram-negative (*E. coli*). One surgical debridement was performed on 52.2% of patients. *Acinetobacter* and *enterococcus* were in our patient wound and treated by two surgical debridements. In such cases, appropriate antibiotherapy is valuable and biochemical parameters are controlled regularly.

Chordomas extend from caudal to cephalad during growth, hereby greater cephalad extension chordomas increase disease recurrence and reduce survival [10].

Chordoma size is related with progressive local recurrence by greater than 10 cm, in which size recurrence rate is 46% [11]. In the other side, Ruggieri et al reported that with tumor size greater than 500 cm<sup>3</sup> and less than 500 cm<sup>3</sup>, infection rate is 85-74% 1 month postoperatively; after 6 months, the rate is 60-54% [9].

## References

1. Capanna R, Briccoli A, Campanacci LC, et al. Benign and malignant tumors of the sacrum. In: Frymoyer JW, Ducker TB, Hadler NM, et al, eds. *The Adult Spine: Principles and Practice*. 2nd ed. Philadelphia, PA: Lippincott-Raven. 1997:2367-2405.
2. Sung HW, Shu WP, Wang HM, Yuai SY, Tsai YB. Surgical treatment of primary tumors of the sacrum. *Clin Orthop Relat Res*. 1987;(215):91-98.
3. Unni KK. *Dahlin's Bone Tumors: General Aspects and Data on 11,087 Cases*. 5th ed. Philadelphia, PA: Lippincott-Raven; 1997.
4. Samson IR, Springfield DS, Suit HD, Mankin HJ. Operative treatment of sacrococcygeal chordoma. A review of twenty-one cases. *J Bone Joint Surg Am*. 1993;75(10):1476-1484.
5. Chen KW, Yang HL, Lu J, Liu JY, Chen XQ. Prognostic factors of sacral chordoma after surgical therapy: a study of 36 patients. *Spinal Cord*. 2010;48(2):166-171.
6. Cheng EY, Ozerdemoglu RA, Transfeldt EE, Thompson RC, Jr. Lumbosacral chordoma. Prognostic factors and treatment. *Spine (Phila Pa 1976)*. 1999;24(16):1639-1645.
7. Nakai S, Yoshizawa H, Kobayashi S, Maeda K, Okumura Y. Anorectal and bladder function after sacrifice of the sacral nerves. *Spine (Phila Pa 1976)*. 2000;25(17):2234-2239.
8. Fuchs B, Dickey ID, Yaszemski MJ, Inwards CY, Sim FH. Operative management of sacral chordoma. *J Bone Joint Surg Am*. 2005;87(10):2211-2216.
9. Ruggieri P, Angelini A, Pala E, Mercuri M. Infections in surgery of primary tumors of the sacrum. *Spine (Phila Pa 1976)*. 2012;37(5):420-428.
10. Yang H, Zhu L, Ebraheim NA, Liu X, Castillo S, Tang T, Liu J, et al. Analysis of risk factors for recurrence after the resection of sacral chordoma combined with embolization. *Spine J*. 2009;9(12):972-980.
11. Ozger H, Eralp L, Sungur M, Atalar AC. Surgical management of sacral chordoma. *Acta Orthop Belg*. 2010;76(2):243-253.