

# Retroperitoneal, Abdominal, and Pelvic Abscess in Appendicitis: The Limitation of Diagnostic Modalities

Rafay Khan<sup>a, b</sup>, Sunil Tulpule<sup>a</sup>, Kalyani Regeti<sup>a</sup>, Mohammad Amir Hossain<sup>a</sup>

## Abstract

Acute appendicitis is a common and well-recognized condition that can be easily managed. However, at times it can become significantly complicated and thus life-threatening. Acute appendicitis can present atypically with findings such as peritonitis and even abdominal abscesses. During laparotomy it is highly unusual to find signs of peritonitis that were not initially visualized by abdominal imaging studies consisting of retroperitoneal and pelvic abscesses. In this case report, we describe the diagnosis and management of a 62-year-old female discovered to have several retroperitoneal abdominal and pelvic abscesses complicated by peritonitis discovered during exploratory laparotomy at the time of appendectomy. The presentation of appendicitis has been associated with abdominal abscesses and peritonitis; however, these findings may at times not be seen using CT imaging. Furthermore, retroperitoneal abscess is a relatively uncommon finding associated with appendicitis. Through this report, we plan to illustrate the importance of not neglecting the possibility of particular intra-abdominal and extra-abdominal inflammatory conditions which may arise during the surgical management of appendicitis.

**Keywords:** Appendicitis; Diagnosis; Abscess; Retroperitoneal; CT scan

## Introduction

Acute appendicitis with an underlying presentation of peritonitis and abscess can result in prolonged hospital stay and duration of treatment. Such complications need to be reinforced in order to prevent further adverse effects. Intra-abdominal abscesses have been shown to complicate many illnesses, some of which include appendicitis, pancreatitis, diverticulitis, and

may even present during a postoperative time period. However, retroperitoneal abscess can also develop and as it is uncommon, it may be missed both during imaging and surgery. The mortality associated with undiagnosed and untreated abscesses is relatively high and thus must be taken into consideration when treating appendicitis, especially when associated with peritonitis. Although physicians can diagnose abscesses with the use of ultrasonography or computed tomography (CT) scan, as seen in this case report, this is not always the case and thus needs to remain within a physician's differential when managing appendicitis. At times, it can also be associated with retroperitoneal and pelvic abscesses which may go overlooked and worsen a patient's clinical outcome especially when not diagnosed preoperatively.

## Case Report

A 62-year-old female with no significant past medical history other than morbid obesity presented to the emergency department with complaints of abdominal pain. The patient stated that the abdominal pain was of sudden onset and began 4 days prior. She did not initially see a physician until the pain got progressively worse leading to several episodes of non-bloody, non-bilious vomiting. The pain started in the right lower quadrant and subsequently turned into diffuse abdominal pain. Patient denied any symptoms of fevers, chills, diarrhea, constipation, or any other associated aggravating or alleviating symptoms.

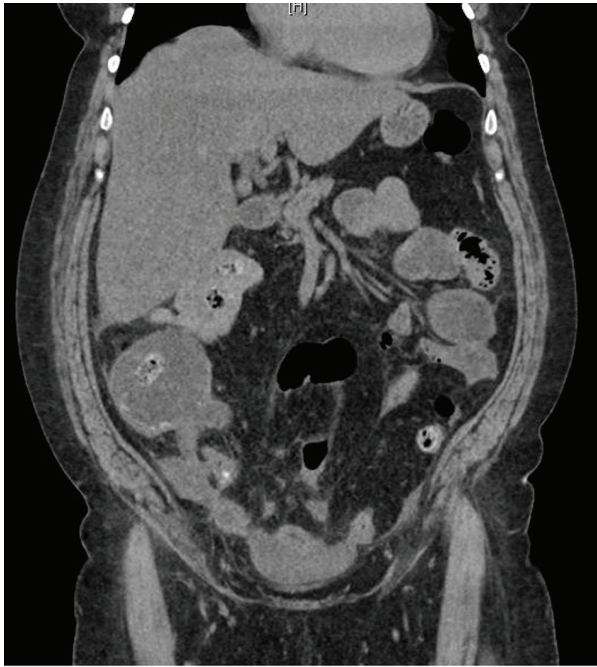Vital signs on presentation showed a blood pressure of 128/60 mm Hg, pulse of 90/min, respiratory rate of 18/min, and temperature of 99.8 °F. Pertinent findings on physical examination showed a diffuse mild abdominal tenderness with a localized point of significant tenderness in the right lower quadrant. Bowel sounds were present and there were no signs of abdominal distention. Initial laboratory data demonstrated a white blood cell count of  $17.1 \times 10^3/\mu\text{L}$ , hemoglobin of 14.8 g/dL, hematocrit of 45%, and platelets of  $363 \times 10^3/\mu\text{L}$ . Na was 129 mmol/L, potassium was 3.5 mmol/L, chloride was 87 mmol/L, bicarbonate was 27 mmol/L, blood urea nitrogen was 39 mg/dL, creatinine was 1.3 mg/dL, and glucose was 153 mg/dL. Other findings showed an amylase of 12 U/L, lipase of 10 U/L, alkaline phosphatase of 137 U/L, aspartate transaminase of 19 U/L, alanine transaminase of 28 U/L, and total bilirubin

Manuscript accepted for publication August 13, 2015

<sup>a</sup>Department of Internal Medicine, Raritan Bay Medical Center, 530 New Brunswick Avenue, Perth Amboy, NJ 08861, USA

<sup>b</sup>Corresponding Author: Rafay Khan, Internal Medicine Department, Raritan Bay Medical Center, 530 New Brunswick Avenue, Perth Amboy, NJ 07733, USA. Email: rafay.t.khan@gmail.com

doi: <http://dx.doi.org/10.14740/jmc2266w>

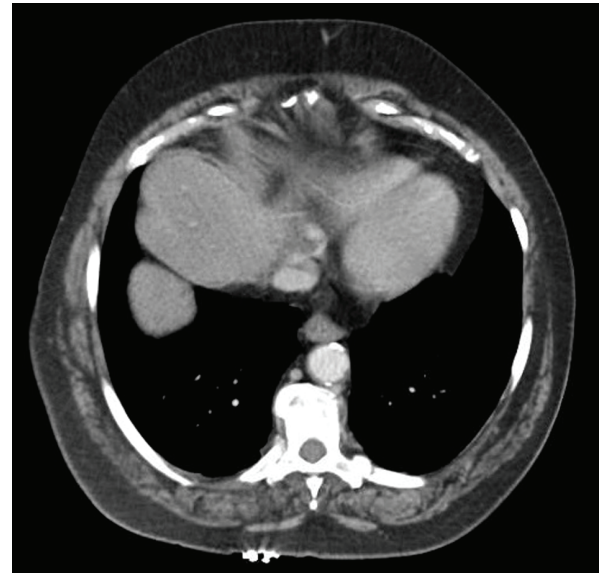


**Figure 1.** CT urogram demonstrating signs of appendicitis.

of 0.8 mg/dL.

CT urogram (Fig. 1) demonstrated an appendix measuring 1.5 cm in caliber with demonstration of a 7-mm appendicolith. There was subtle associated pericecal and periappendiceal mesenteric stranding. The findings were most compatible with acute appendicitis. Additionally there was approximately a 10-cm rounded structure within the pelvis compressing the bladder. As origin of this structure could not be delineated, a CT scan with contrast was performed. Abdomen-pelvis CT with contrast was significant for similar findings (Fig. 2) compatible with acute appendicitis. Additionally there were scattered areas of ascites throughout the mesenteric leaflets with adjacent mesenteric stranding suggestive of peritonitis. There was an area of loculated ascites within the pelvis with the largest area of loculation measuring  $7.6 \times 4.5$  cm causing a mass effect on the bladder.

Patient was evaluated and taken to the operating room by surgery. Initially laparoscopic techniques were attempted which revealed multiple areas of abdominal abscesses including retroperitoneal abscesses and as the small intestine was grossly distended from an obvious ileus from the peritonitis, exploratory laparotomy was initiated. The patient's abdominal cavity revealed small intestinal loops, which were grossly attached to each other from peritonitis. There was additionally the presence of two separate large pelvic abscesses, which required irrigation and drainage. The grossly necrotic appendix was gradually dissected using a Harmonic scalpel and appeared to be gangrenous and was clearly perforated at the time. Fecalith was also found to be within the appendix. The abdominal cavity was heavily irrigated with 10 L of sterile normal saline. Fibrinous peel was removed from the patient's intestine. A flat 10 French Jackson-Pratt drain was left in place in order to prevent further abscess formations.



**Figure 2.** CT abdomen showing dilated signs of significant ascites.

Postoperatively, the patient experienced some respiratory distress and was monitored in the intensive care unit on BiPap. She improved over the course of several days with the use of zosyn and flagyl which was later adjusted to ceftriaxone as peritoneal cultures grew *Escherichia coli*.

## Discussion

Diagnostic imaging as described above is not always a reliable method in demonstrating underlying complications associated with appendicitis. Through this discussion we will analyze the importance for a physician to be aware of these findings including but not limited to the various locations of abscesses, peritonitis, and the risks that may be associated with these complications if they go overlooked. Acute appendicitis is a relatively common condition and carries a low morbidity and mortality rate through the use of effective diagnosis and management [1, 2]. In most cases of appendicitis which are non-perforated, they can be treated with urgent appendectomy. However, in cases where there is perforated appendicitis, there may be a formation of abscess, commonly in the right iliac fossa or in the pelvic cavity, which is either treated by early appendectomy or appendectomy followed by percutaneous drainage [3, 4].

Development of retroperitoneal abscess is of the rarer and serious complications associated with the perforation of retrocecal appendix, normally due to its delayed diagnosis and treatment [3, 5, 6]. In our case, the patient was found to have several sites of both abdominal including retroperitoneal and pelvic abscesses. Due to the urgent laparotomy, fortunately complication of the retroperitoneal abscesses was limited as it was evidently discovered. However few reports in the literature have demonstrated cases of appendicitis complicated by retroperitoneal abscesses resulting in emphysema in psoas and thigh which can be highly detrimental to a patient's condition

[3, 5-7].

CT scan is the most common used imaging modality for the diagnosis of appendicitis. In the literature, it has been shown to be highly effective in demonstrating the formation of abscesses in patients with appendicitis. However, in our case abdominal abscesses were not noted on CT, as they may have been hidden by overlying signs of ascites and peritonitis. CT scan normally helps in the diagnosis and can help with surgical planning. If abscess is demonstrated, the plan for drainage can be determined and thus conducted either percutaneously via a retroperitoneal approach or by laparotomy. Moreover, our case illustrates that CT imaging can have its limitations which can impact a patient's outcome and surgical approach.

Only about 2-7% of patients with appendicitis manifest with complex features such as abscesses; however, if not managed appropriately it can result in potential septic shock [8]. Progression of a retroperitoneal abscess from a perforated appendicitis is unusual and difficult to diagnose as it may lack classical symptoms of acute appendicitis at the onset of the condition and normally may not be associated with peritonitis, thus final diagnosis may only be achieved during surgery [9]. Our patient, although was discovered to have retroperitoneal abscesses also had co-presentation of peritonitis associated with abdominal and pelvic abscesses. Ultrasound has been used previously as it is highly available and inexpensive but it requires a high level of technical expertise. CT scan on the other hand is very accurate and also non-invasive. Imaging modalities such as a multidetector CT (MDCT) may be found to be more efficient in determining underlying complications of appendicitis. In a retrospective study of 244 patients with MDCT scan analysis demonstrated that abscess (99%), extraluminal gas (98%), and ileus (93%) had the high specificities; however, their sensitivities were low (34%, 35%, and 53%) and thus relying on these features may result in missed perforation in half of these patients [9]. In another study of 94 patients, the presence of either extraluminal gas, abscess, phlegmon, extraluminal appendicololith, or appendicular wall enhancement defect was 96.4% sensitive and 100% specific for perforated appendicitis [9]. Although, these findings suggest perforated appendicitis, the reverse rationale may not apply. Appendicitis often seen on CT scan may or may not be associated with various locations of abscess formations.

Research and retrospective studies have yet to demonstrate the sensitivity and specificity of CT imaging in locating retroperitoneal and abdominal abscesses found in patients during surgical exploration but not via diagnostic imaging. Thus, physicians need to be aware that although CT imaging may not demonstrate these findings, during appendectomy especially of a perforated appendix, a proper examination needs to be conducted to rule out underlying abscess collections.

## Grant Support

None.

## Financial Disclosures

None.

## Conflict of Interest

This is to state that there has been no activity or involvements that will raise the question of bias in this case report or any of the conclusions or opinions that it stands for.

## References

1. Hale DA, Molloy M, Pearl RH, Schutt DC, Jaques DP. Appendectomy: a contemporary appraisal. *Ann Surg.* 1997;225(3):252-261.
2. Blomqvist PG, Andersson RE, Granath F, Lambe MP, Ek-bom AR. Mortality after appendectomy in Sweden, 1987-1996. *Ann Surg.* 2001;233(4):455-460.
3. Hsieh CH, Wang YC, Yang HR, Chung PK, Jeng LB, Chen RJ. Extensive retroperitoneal and right thigh abscess in a patient with ruptured retrocecal appendicitis: an extremely fulminant form of a common disease. *World J Gastroenterol.* 2006;12(3):496-499.
4. Lally KP, Cox CS, Andrassy RJ. Appendix. In: Townsend CM, Beauchamp RD, Evers BM, Mattox KL; Sabiston textbook of surgery. 17th ed. Philadelphia: Elsevier Saunders, 2004;1381-1399.
5. Gutknecht DR. Retroperitoneal abscess presenting as emphysema of the thigh. *J Clin Gastroenterol.* 1997;25(4):685-687.
6. Edwards JD, Eckhauser FE. Retroperitoneal perforation of the appendix presenting as subcutaneous emphysema of the thigh. *Dis Colon Rectum.* 1986;29(7):456-458.
7. Sharma SB, Gupta V, Sharma SC. Acute appendicitis presenting as thigh abscess in a child: a case report. *Pediatr Surg Int.* 2005;21(4):298-300.
8. Kim JK, Ryoo S, Oh HK, Kim JS, Shin R, Choe EK, Jeong SY, et al. Management of appendicitis presenting with abscess or mass. *J Korean Soc Coloproctol.* 2010;26(6):413-419.
9. Mates IN, Constantinoiu S. Intermesenteric appendicular abscess, a diagnostic challenge; case report and review. *Chirurgia (Bucur).* 2014;109(2):275-279.