

# Acquired Immune Deficiency Syndrome Cholangiopathy: Case Series of Three Patients and Literature Review

Yasir Ahmed<sup>a, f</sup>, Mustafeez Ur Rahman<sup>b</sup>, Zoia Ehsan Khattak<sup>c</sup>,  
Jorge Herrera<sup>d</sup>, Eduardo Calderon<sup>e</sup>

## Abstract

Cholangiopathy in acquired immune deficiency syndrome (AIDS) is being less frequently reported since antiretroviral therapy (ART) is available. It is associated with an advanced disease and seen in situations with poor access or non-compliance with ART. Liver biopsy is thought to have low yield in cases of AIDS cholangiopathy, but it can be an important tool in diagnosis, especially early in the course of the disease. The prognosis of AIDS cholangiopathy is generally not favorable, the therapy for opportunistic infections is mostly ineffective and restoration of immune system with ART remains the therapy of choice. We are sharing our experience of diagnosing and managing three cases of AIDS cholangiopathy.

**Keywords:** AIDS cholangiopathy; HIV/AIDS; Opportunistic infections; Antiretroviral therapy

## Introduction

The cholangiopathy seen in patients with acquired immune deficiency syndrome (AIDS) is believed to have an infectious etiology, has characteristic cholangiographic findings, and is associated with advanced AIDS and low CD4 count [1-5]. Biliary tract abnormalities in AIDS patients were initially reported in the 1980s [6, 7]. AIDS cholangiopathy is commonly

reported in young men who have sex with men with a mean age of 37 years [8, 9], and in heterosexual men in developing countries [10]. The true incidence of AIDS cholangiopathy is unknown and its incidence has decreased significantly since the initiation of antiretroviral therapy (ART) in mid-1990s [11]. Earlier studies estimated AIDS cholangiopathy to occur in 26% of patients with AIDS [11, 12] and one popular study early in 1990s estimated the prevalence to be as high as 30% in patients with chronic AIDS-related diarrhea [12]. It is now primarily seen in instances of poor access to ART and medication non-compliance, particularly in those with extremely low CD4 counts and opportunistic infections, as well as those with drug-resistant human immunodeficiency virus (HIV) infection [13]. We present three cases with relatively unique presentation and diagnostic challenges, our experience of managing these patients and the outcome.

## Case Reports

### Case 1

#### *Investigations*

A 28-year-old female with HIV infection and AIDS, and asthma, presented to the emergency department with acute onset abdominal pain, more so in the right upper quadrant (RUQ), for 1 week and increasing abdominal swelling for 3 days. She endorsed associated symptoms of nausea, vomiting and subjective fever and chills. She was afebrile and vitally stable on presentation, and abdomen was soft, though mildly distended and was diffusely tender to palpation. Scattered ecchymosis was also noticed on bilateral lower extremities. She was not able to adhere to ART or opportunistic infection prophylaxis (OIP).

#### *Diagnosis*

Pertinent laboratory data are mentioned in Table 1.

Rest of the laboratory data were within normal limit. Abdominal ultrasound (US) showed features suggestive of cirrhosis associated with hepatomegaly and ascites, but no evidence of intrahepatic biliary ductal dilation or evidence

Manuscript submitted August 18, 2022, accepted September 22, 2022  
Published online September 28, 2022

<sup>a</sup>Department of Internal Medicine, United Health Services Hospital (UHS), Binghamton, NY, USA

<sup>b</sup>PGY-III Internal Medicine at University of South Alabama Health University Hospital, Mobile, AL, USA

<sup>c</sup>Khyber Teaching Hospital, Peshawar, Pakistan

<sup>d</sup>Section of Hepatology, Department of Internal Medicine, USA Health, Mobile, AL, USA

<sup>e</sup>Department of Internal Medicine and Infectious Diseases, University of South Alabama Health University Hospital, Mobile, AL, USA

<sup>f</sup>Corresponding Author: Yasir Ahmed, Department of Internal Medicine, United Health Services Hospital (UHS), Binghamton, NY, USA.  
Email: yasir.ahmed.ktk@gmail.com

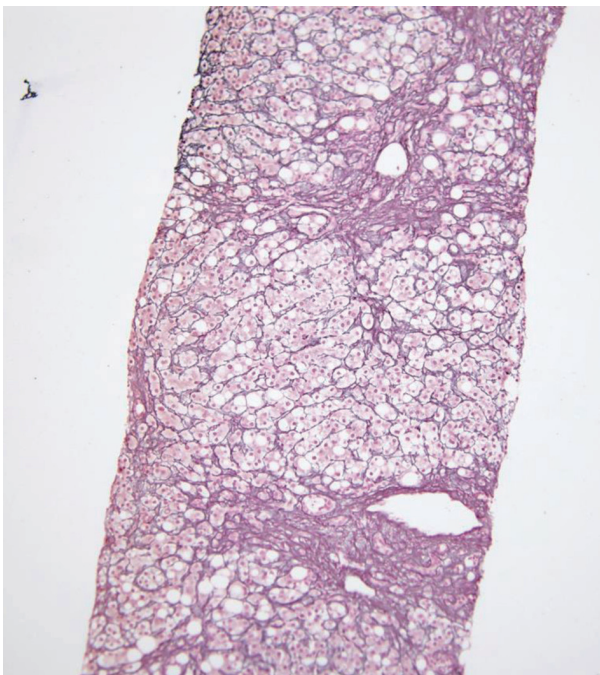
doi: <https://doi.org/10.14740/jmc3998>

**Table 1.** Laboratory Workup for Case 1

Laboratory test	Value reported	Reference range
White blood cell (WBC)	14	4.3 - 11 × 10 <sup>3</sup> /μL
Platelets	72	150 - 400 × 10 <sup>3</sup> /μL
CD4 count	18	463 - 1,685/μL
Alkaline phosphatase (ALP)	345	46 - 116 U/L
Gamma glutamyl transferase (GGT)	125	15 - 85 U/L
Alanine aminotransferase (AST)	292	15 - 37 U/L
Albumin	2.3	3.4 - 5 g/dL
Internationalized ratio (INR)	1.09	0.8 - 1.2
Serum ascites albumin gradient (SAAG)	0.9	< 1.1

of stones in the bile duct. Computed tomography (CT) scan of the abdomen with contrast showed hepatosplenomegaly and portal vein enlargement suggestive of portal hypertension.

Ascitic fluid analysis showed no evidence of spontaneous bacterial peritonitis (SBP). Hepatitis serologies excluded acute or chronic viral hepatitis. To further define the liver disease, a trans-jugular biopsy of the liver was performed which showed portal inflammation, cholangitis, ductular reaction, mild lobular inflammation, moderate steatosis, pericellular fibrosis without any bridging (Figs. 1-3). Additional data revealed 19,200 copies/μL of cytomegalovirus (CMV) on quantitative serum polymerase chain reaction (PCR). These findings in the setting of the clinical presentation suggested AIDS-related cholangiopathy with CMV infection as the likely etiology.



**Figure 1.** Preserved reticulin network with focal regenerative pattern on reticulin stain.

### Treatment

Highly active retroviral therapy (HAART) was initiated, and the patient showed significant improvement in her symptoms.

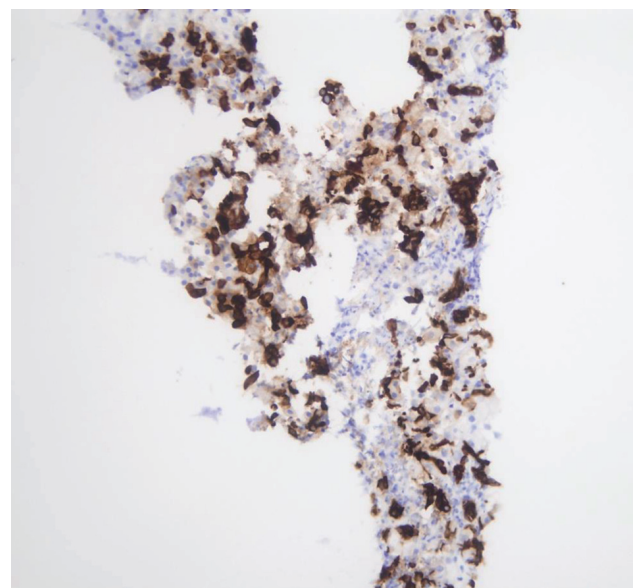
### Follow-up

The patient is doing well on her follow-up in the clinic 30 months after diagnosis.

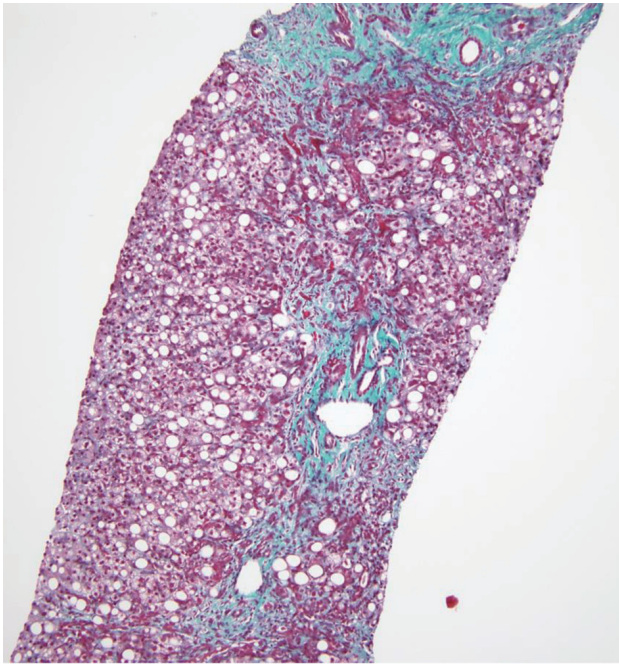
## Case 2

### Investigations

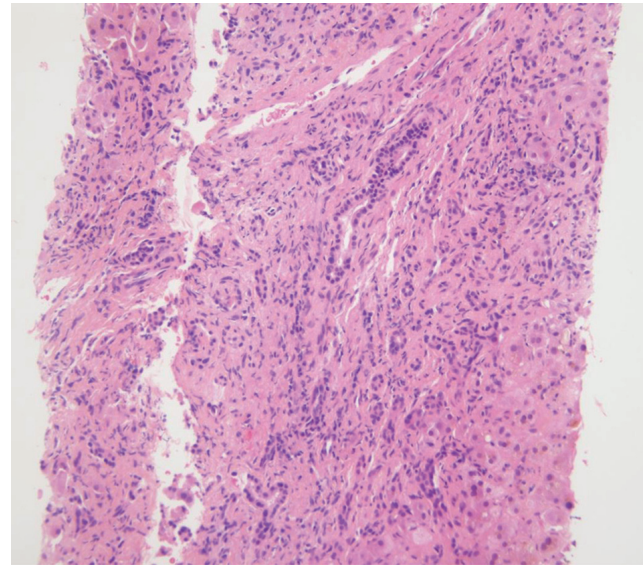
A 38-year-old male with HIV infection, diabetes mellitus type



**Figure 2.** CK7 highlighting ductular reaction and scattered intermediate hepatocytes.



**Figure 3.** Trichrome stain demonstrating pericellular and portal fibrosis without definite bridging.



**Figure 4.** Preserved reticulin network on reticulin stain.

II, and hypertension was transferred from a group home with failure to thrive for 2 months, and lower extremity edema and jaundice for 2 weeks. He also reported diarrhea for over 6 weeks. These symptoms were associated with night sweats, itching, loss of appetite and more than 20 pounds weight loss. On examination, he was vitally stable, had scleral icterus, severe cachexia with temporal wasting and bilateral lower extremity pitting edema. The abdomen was slightly tender to palpation in the RUQ and epigastric region. He reported not being able to take ART and engagement in sexual activity with men including receptive anal intercourse.

*Diagnosis*

Pertinent laboratory data are mentioned in Table 2.

Rest of the liver profile was within normal limit. Stool pathogen testing panel was positive for microsporidium and

quantitative serum PCR for CMV showed 6,910 copies/ $\mu$ L. An abdominal US showed hepatosplenomegaly with normal echogenicity, no evidence of intrahepatic biliary ductal dilatation, no evidence of stones and a small amount of free peritoneal fluid. Ascitic fluid analysis excluded SBP. Magnetic resonance cholangiopancreatography (MRCP) did not show evidence of pancreatic or biliary duct obstruction or cholelithiasis. A trans-jugular liver biopsy revealed cholestatic hepatitis with moderate to marked inflammation, prominent ductular proliferation and portal septal fibrosis with focal bridging (Figs. 4-6). These findings in the setting of AIDS and opportunistic infection with CMV and microsporidium were consistent with the diagnosis of AIDS-related cholangitis. CMV was not identified on rectal biopsy obtained via flexible sigmoidoscopy.

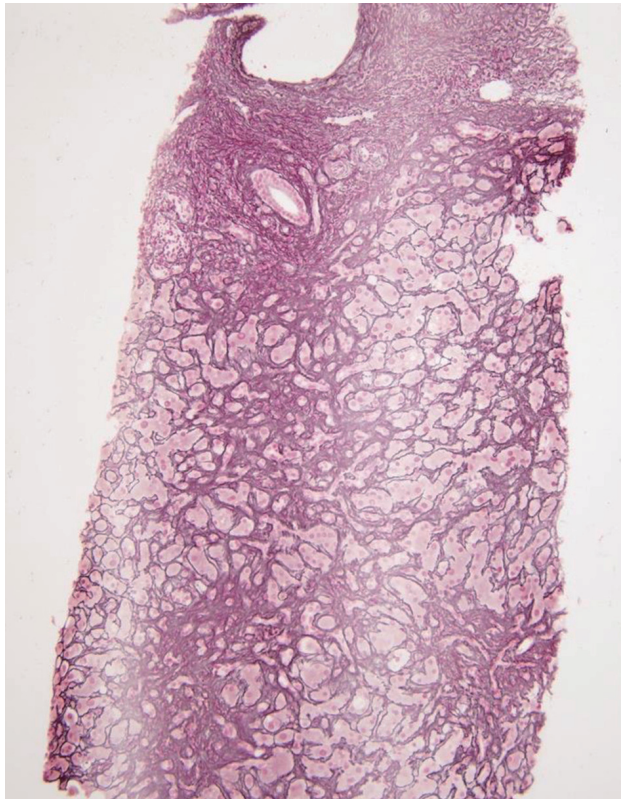*Treatment and follow-up*

Infectious disease team recommended albendazole and deemed that therapy for CMV was not warranted at that time. The patient expired within 4 weeks of diagnosis.

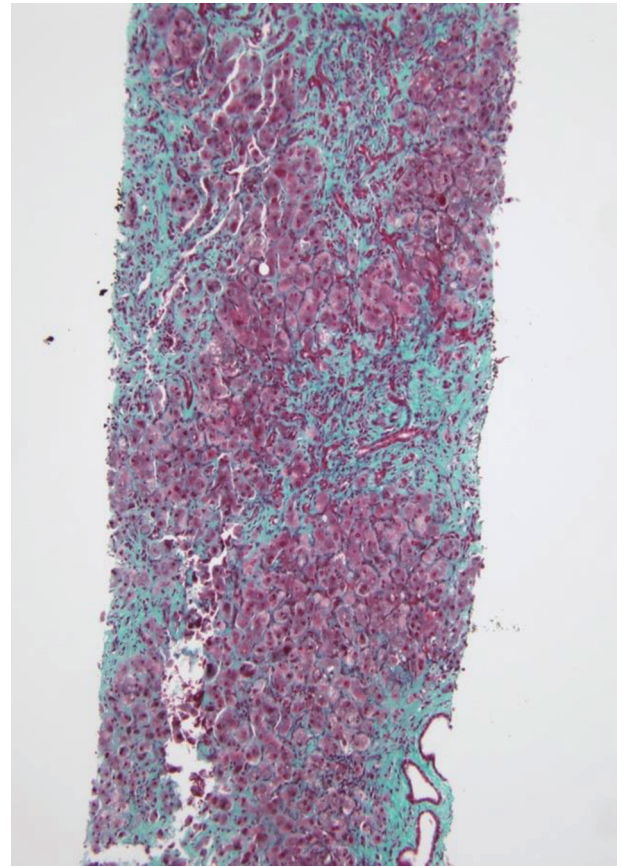
**Table 2.** Laboratory Workup for Case 2

Laboratory test	Value reported	Reference range
Platelets	83	150 - 400 $\times$ 10 <sup>3</sup> / $\mu$ L
CD4 count	241	463 - 1,685/ $\mu$ L
Alkaline phosphatase (ALP)	653	46 - 116 U/L
Gamma glutamyl transferase (GGT)	419	15 - 85 U/L
Total bilirubin	9.0	0.2 - 1.0 mg/dL
Direct bilirubin	7.3	0 - 0.2 mg/dL
Albumin	1.2	3.4 - 5 g/dL
Serum ascites albumin gradient (SAAG)	0.9	< 1.1





**Figure 5.** Lympho-monocytic infiltrate admixed with plasma cells on H&E. H&E: hematoxylin and eosin.



**Figure 6.** Portal tracts expansion by fibrosis with septa formation and focal bridging on trichrome staining.

**Case 3**

*Investigations*

A 27-year-old male with asthma and hypertension visited the gastroenterology clinic for abdominal pain, diarrhea with intermittent blood streaking for 3 - 4 weeks. He also endorsed dysphagia. On physical examination, patient was vitally stable and had slight tenderness in the right upper and left lower quadrant. Digital rectal exam showed anal tags versus condylomas.

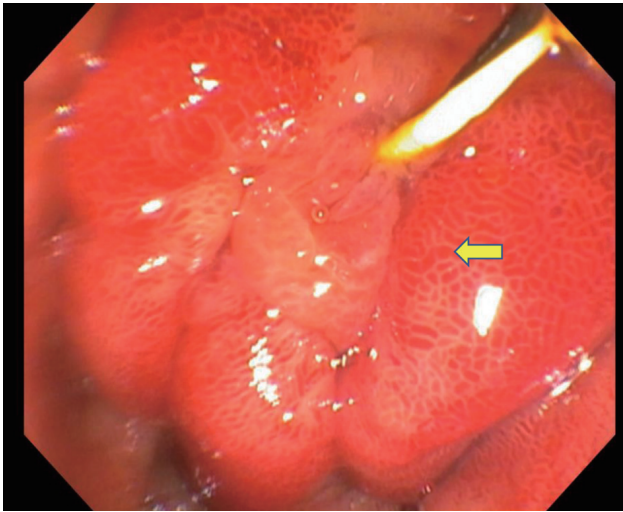
*Diagnosis*

Pertinent laboratory data are mentioned in Table 3.

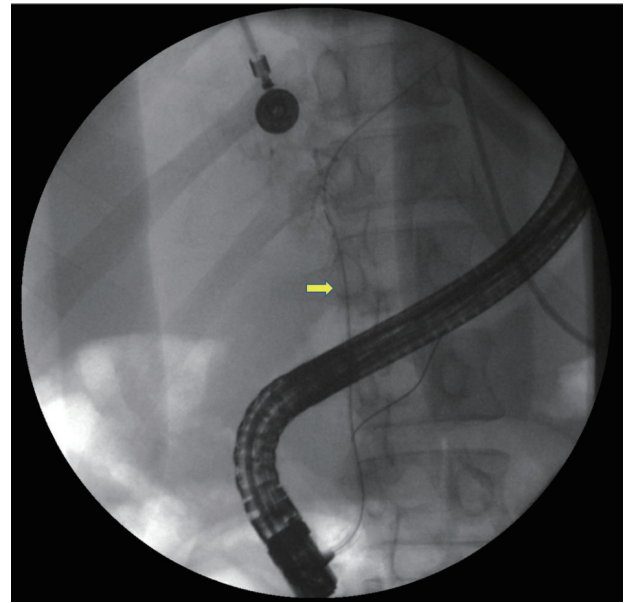
Total bilirubin was elevated and had a rising trend, with a value recorded as high as 15.2 mg/dL. Hepatitis serologies excluded acute or chronic viral hepatitis. HIV antibody testing was positive and a new diagnosis was made in this patient. HIV viral load was high and absolute CD4 count was low as shown in the table. Stool pathogen testing panel was posi-

**Table 3.** Laboratory Workup for Case 3

Laboratory test	Value reported	Reference range
Hemoglobin	8.1	12 - 16 g/dL
Platelets	23	150 - 400 × 10 <sup>3</sup> /μL
Human immunodeficiency virus viral load	119,386	< 20 copies/mL
CD4 count	38	463 - 1,685/μL
Total bilirubin	7.3	0.2 - 1.0 mg/dL
Direct bilirubin	6.3	0 - 0.2 mg/dL
Alkaline phosphatase (ALP)	394	46 - 116 U/L
Gamma glutamyl transferase (GGT)	402	15 - 85 U/L
Albumin	2.1	3.4 - 5 g/dL



**Figure 7.** Major papilla among edematous mucosa and erythema.



**Figure 8.** Minimal or no contrast on the film seen after maximal contrast injection.

tive for microsporidium. Quantitative serum PCR for CMV showed 9,750 copies/mL. Patient underwent flexible sigmoidoscopy and CMV was noted on immune-histochemical stain of rectal tissue biopsy, confirming the diagnosis of disseminated CMV infection.

Abdominal US was normal. MRCP did not show evidence of cholelithiasis or biliary system abnormalities either. An endoscopic retrograde cholangiopancreatography (ERCP) was done as bilirubin was elevated and right intrahepatic system images were missing on MRCP. It showed edematous and strictured common bile duct (CBD) (Fig. 7), from the distal to the proximal portion and its bifurcation. No filling defects were seen. The CBD and common hepatic duct (CHD) were narrowed preventing any contrast from being seen on cholangiogram (Fig. 8). These findings pointed towards a diagnosis of AIDS cholangiopathy.

#### Treatment and follow-up

Albendazole and foscarnet were started on the recommendation of infectious disease team. Tenofovir and emtricitabine were initiated for the new diagnosis of HIV.

Patient had a prolonged hospital stay and continued to decline clinically. He expired within a month of diagnosis of AIDS cholangiopathy.

A summary of cases is shown in Table 4.

## Discussion

AIDS cholangiopathy is thought to be caused by opportunistic infections in the biliary tract and in the setting of advanced immunosuppression [13]. The most common pathogen is *Cryptosporidium parvum* (*C. parvum*), isolated in up to 57% of patients [4]. *In vitro* studies suggest that *C. parvum* induces apoptotic cell death through Fas/Fas ligand (FasL) system and synergistic effects of the HIV-1 trans-activator of transcription

(Tat) protein [14]. Another proposed mechanism is autonomic nerve damage caused by *C. parvum*, resulting in sphincter of Oddi dysfunction and papillary stenosis and CBD dilation [5]. Epidemiologic studies support the role of cryptosporidium as an etiologic agent of AIDS cholangiopathy [12]. CMV is the next-most common pathogen implicated in the pathogenesis of AIDS cholangiopathy, estimated to cause up to 20% of cases of AIDS cholangiopathy [13]. CMV damages the arterioles adjacent to the biliary canaliculi leading to ischemic damage in the biliary tree [1].

Microsporidia particularly *Enterocytozoon bienewsi* (*E. bienewsi*) and isospora have been found to be associated with AIDS cholangiopathy in a small percentage of patients, often in association with chronic diarrhea [13]. Cyclospora, giardia and *Mycobacterium avium* intracellulare (MAI) complex are very rare causes, contributing to less than 5% cases [1, 15, 16], while in some cases, no infectious pathogen is identified.

Clinically, AIDS cholangiopathy may be asymptomatic, but in most cases, RUQ pain (99%) is the most common presenting symptom, usually most severe in those with papillary stenosis [13]. Fever, nausea and vomiting, and jaundice are less common [3, 8, 10, 13]. Other symptoms may include diarrhea and symptoms of malabsorption, more commonly seen with microsporidium, cryptosporidium, or MAI infection [12, 17].

Serologic testing usually reveals profound immunosuppression with a low CD4 count. Liver tests are elevated in a cholestatic pattern as evidenced by marked increase in alkaline phosphatase (ALP) and gamma glutamyl transferase (GGT) levels in 80% of cases [3, 5, 8-13]. Transaminases are usually mildly elevated, and total bilirubin level is often normal or slightly elevated [5, 10, 13].

The diagnosis of AIDS cholangiopathy is usually established by imaging studies and/or liver biopsy. Abdominal US is the most common initial imaging modality [5]. Intra- or ex-



**Table 4.** Summary of Cases

Presentation	Abdominal pain and tenderness on abdominal exam; Diarrhea; Jaundice	3/3 (100%) patients; 2/3; 1/3
Laboratory data	Cholestatic pattern of liver injury with ALP	3/3 (100%)
HIV status	Advanced AIDS; CMV by PCR; <i>Cryptosporidium parvum</i>	All three patients; All three patients; 1/3 patients
Imaging	Abdominal ultrasound; MRCP; ERCP	No biliary abnormalities noted; 2/3 within normal limit; 1/3 with abnormal findings
Histopathology	Liver biopsy	Findings of cholangitis in 2/3 patients
Treatment	ART; Treatment of opportunistic infection	2/3 patients; 2/3 patients
Prognosis	Two patient's non-adherent to ART and third case was a new diagnosis	One patient with good response to ART and alive at 30 months; Second and third patients expired within a month of diagnosis despite treatment

HIV: human immunodeficiency virus; ALP: alkaline phosphatase; AIDS: acquired immune deficiency syndrome; PCR: polymerase chain reaction; CMV: cytomegalovirus; MRCP: magnetic resonance cholangiopancreatography; ERCP: endoscopic retrograde cholangiopancreatography; ART: antiretroviral therapy.

trahepatic biliary dilation is the most common finding, but in early cases, it may be normal [9, 18, 19]. In two-thirds of the patients, an echogenic nodule at the distal end of CBD is noticed, which correlates with ampullary edema on ERCP [19].

In most cases, MRCP is performed to confirm or establish the diagnosis. One of the following four patterns is seen on cholangiography with MRCP or ERCP: 1) sclerosing cholangitis in combination with papillary stenosis (seen in 50% cases); 2) papillary stenosis alone; 3) combined intrahepatic and extrahepatic sclerosing cholangitis without papillary stenosis; and 4) long extrahepatic bile duct strictures with or without intrahepatic sclerosing cholangitis. MRCP is preferred over ERCP as it is non-invasive, does not have the risks of iatrogenic complications and is as sensitive as ERCP. The characteristic beaded appearance of sclerosing cholangitis is seen in only 20% of patients [1, 3, 9, 18-21]. Contrast-enhanced CT scan has a limited role in diagnosis and is most helpful in excluding other causes of cholestasis [22].

In the absence of typical cholangiographic findings, liver biopsy is often used to make the diagnosis. Findings similar to sclerosing cholangitis in non-AIDS patients are seen on liver biopsy in up to 50% in AIDS cholangiopathy [23]. Liver biopsy is most useful in early cases that have not developed the classical findings on cholangiography [24]. It can also exclude other potential causes of elevated liver tests and in some cases, help identify opportunistic organism causing cholestatic injury [25].

The management of AIDS cholangiopathy is mostly supportive and geared towards restoration of immune system. Treatment of opportunistic infections leading to AIDS cholangiopathy is rarely affective unless the immune system is restored. Nitazoxanide is the only US Food and Drug Administration (FDA) approved drug for cryptosporidium [26]. It is effective in 93% of non-AIDS patients [27], but the effectiveness is not replicated in AIDS patients [28]. Paromomycin is less effective alternative therapy for cryptosporidiosis in AIDS [17, 29], and azithromycin, spiramycin and bovine anti-cryptosporidium immunoglobulin were reported to be effective in some case series but were ineffective in controlled trials in AIDS patients and these trials were unfortunately never published [30].

CMV-directed treatment in AIDS cholangiopathy is rarely effective. Intravenous ganciclovir and foscarnet have shown no benefit [3, 9, 23, 31]. In microsporidia, transient therapeutic effect has been reported with albendazole [32]. There is some success reported with trimethoprim/sulfamethoxazole (TMP-SMX) for the treatment of *Cyclospora* in AIDS [33, 34], while it is recommended to combine TMP-SMX with ivermectin for *isospora* [35].

Ursodeoxycholic acid (UDSA) is a bile acid often used in the treatment of cholestatic liver disease. The experience in AIDS is very limited. Relief of abdominal pain and decreasing serum ALP was reported in four patients who were treated with URSO at 10 mg/kg/day [36]. No data on long-term benefit were provided.

ART appears to be the best treatment option for AIDS cholangiopathy that helps by restoring immune system, thus improving the probability of remaining free of AIDS and improved survival [37, 38]. It has also been shown to modify the course of disease and eradicate cryptosporidiosis and microsporidiosis in HIV-positive patients with diarrhea when a combination of ART is used [39, 40]. A combination ART including protease inhibitor resulted in restoration of immunity and clinical, microbiologic, and histologic response in eight out of nine HIV-infected patients with chronic gastrointestinal cryptosporidiosis, microsporidiosis, or both, while antimicrobial therapy with paromomycin, albendazole, and azithromycin was not effective in the same study [41]. In some patients, progression of AIDS cholangiopathy occurs despite successful ART therapy, suggesting that delay in diagnosis may lead to irreversible damage of the biliary system [42-44].

For patients with papillary stenosis, ERCP with sphincterotomy may provide a symptomatic relief. A statistically significant decrease in abdominal pain score after biliary sphincterotomy compared with a pre-procedure score was seen at 3.9 months follow-up in 12 out of 13 patients who underwent sphincterotomy during ERCP for papillary stenosis alone or in combination with sclerosing cholangitis [1]. In a study of 25 patients with AIDS associated with biliary stenosis who underwent ERCP sphincterotomy, patients were followed up long term ( $9.4 \pm 1.2$  months) and significant improvement was seen in abdominal pain score,

while serum ALP remained essentially unchanged [2].

The prognosis of AIDS cholangiopathy is generally poor and is attributed to the presence of advanced AIDS. Median survival rates of 7 - 12 months in the pre-ART era have improved to 34 months. The presence of opportunistic infections and marked elevation of ALP appear to be associated with poor prognosis [45].

## Conclusion

Since the introduction of HAART, the incidence of AIDS cholangiopathy has dramatically decreased. Individuals presenting with AIDS and elevated liver tests in a cholestatic pattern require aggressive evaluation to exclude AIDS cholangiopathy as delayed diagnosis results in irreversible biliary damage and poor prognosis. Liver biopsy is an important investigative tool in cases where classical findings on cholangiography are not present.

## Learning points

Early recognition is important and AIDS cholangiopathy should be differentiated from other infectious diseases of the gastrointestinal tract.

Liver biopsy is an important diagnostic tool, especially earlier in the course of the disease.

Treatment with ART should be initiated in attempt to restore immune system.

## Acknowledgments

None to declare.

## Financial Disclosure

None to declare.

## Conflict of Interest

None to declare.

## Informed Consent

An consent was obtained from the patient for publication from one patient for publication of this case report and any accompanying images. We could not reach the next of kin for the other two patients who had expired.

## Author Contributions

Yasir Ahmed contributed to the conceptualization, drafting the case series, introduction and case presentations, literature

review, and final review and editing. Mustafeez Ur Rahman: contributed to the literature review in the preliminary draft, collecting pictures/slides and checking references. Zoia Ehsan Khattak contributed to the literature review in the preliminary draft. Jorge Herrera contributed to the review and editing of the draft and revision to improve suitability for publication. Eduardo Calderon, supervisor, contributed to the conceptualization, review and editing the draft and final review of the draft.

## Data Availability

The authors declare that data supporting the findings of this study are available within the article.

## Abbreviations

HIV: human immunodeficiency virus; AIDS: acquired immune deficiency syndrome; ART: antiretroviral therapy; HAART: highly active antiretroviral therapy; RUQ: right upper quadrant; OIP: opportunistic infection prophylaxis; ALT: alanine transaminase; AST: aspartate aminotransferase; ALP: alkaline phosphatase; GGT: gamma glutamyl transferase; SBP: spontaneous bacterial peritonitis; PCR: polymerase chain reaction; MRCP: magnetic resonance cholangiopancreatography; ERCP: endoscopic retrograde cholangiopancreatography; CBD: common bile duct; CHD: common hepatic duct; *E. bienersi*: *Enterocytozoon bienersi*; CMV: cytomegalovirus; *C. parvum*: *Cryptosporidium parvum*; FDA: Food and Drug Administration; TMP-SMZ: trimethoprim/sulfamethoxazole; UDCA: ursodeoxycholic acid

## References

1. Cello JP. Acquired immunodeficiency syndrome cholangiopathy: spectrum of disease. *Am J Med.* 1989;86(5):539-546.
2. Cello JP, Chan MF. Long-term follow-up of endoscopic retrograde cholangiopancreatography sphincterotomy for patients with acquired immune deficiency syndrome papillary stenosis. *Am J Med.* 1995;99(6):600-603.
3. Bouche H, Housset C, Dumont JL, Carnot F, Menu Y, Aveline B, Belghiti J, et al. AIDS-related cholangitis: diagnostic features and course in 15 patients. *J Hepatol.* 1993;17(1):34-39.
4. Wilcox CM, Monkemuller KE. Hepatobiliary diseases in patients with AIDS: focus on AIDS cholangiopathy and gallbladder disease. *Dig Dis.* 1998;16(4):205-213.
5. Yusuf TE, Baron TH. AIDS Cholangiopathy. *Curr Treat Options Gastroenterol.* 2004;7(2):111-117.
6. Blumberg RS, Kelsey P, Perrone T, Dickersin R, Laquaglia M, Ferruci J. Cytomegalovirus- and Cryptosporidium-associated acalculous gangrenous cholecystitis. *Am J Med.* 1984;76(6):1118-1123.
7. Margulis SJ, Honig CL, Soave R, Govoni AF, Moura-

- dian JA, Jacobson IM. Biliary tract obstruction in the acquired immunodeficiency syndrome. *Ann Intern Med.* 1986;105(2):207-210.
8. De Angelis C, Mangone M, Bianchi M, Saracco G, Repici A, Rizzetto M, Pellicano R. An update on AIDS-related cholangiopathy. *Minerva Gastroenterol Dietol.* 2009;55(1):79-82.
  9. Benhamou Y, Caumes E, Gerosa Y, Cadranet JF, Dohin E, Katlama C, Amouyal P, et al. AIDS-related cholangiopathy. Critical analysis of a prospective series of 26 patients. *Dig Dis Sci.* 1993;38(6):1113-1118.
  10. Devarbhavi H, Sebastian T, Seetharamu SM, Karanth D. HIV/AIDS cholangiopathy: clinical spectrum, cholangiographic features and outcome in 30 patients. *J Gastroenterol Hepatol.* 2010;25(10):1656-1660.
  11. Chen XM, Keithly JS, Paya CV, LaRusso NF. Cryptosporidiosis. *N Engl J Med.* 2002;346(22):1723-1731.
  12. Vakil NB, Schwartz SM, Buggy BP, Brummitt CF, Kherelah M, Letzer DM, Gilson IH, et al. Biliary cryptosporidiosis in HIV-infected people after the waterborne outbreak of cryptosporidiosis in Milwaukee. *N Engl J Med.* 1996;334(1):19-23.
  13. Naseer M, Dailey FE, Juboori AA, Samiullah S, Tahan V. Epidemiology, determinants, and management of AIDS cholangiopathy: A review. *World J Gastroenterol.* 2018;24(7):767-774.
  14. O'Hara SP, Small AJ, Gajdos GB, Badley AD, Chen XM, Larusso NF. HIV-1 Tat protein suppresses cholangiocyte toll-like receptor 4 expression and defense against *Cryptosporidium parvum*. *J Infect Dis.* 2009;199(8):1195-1204.
  15. Farman J, Brunetti J, Baer JW, Freiman H, Comer GM, Scholz FJ, Koehler RE, et al. AIDS-related cholangiopancreatographic changes. *Abdom Imaging.* 1994;19(5):417-422.
  16. Pol S, Romana C, Richard S, Carnot F, Dumont JL, Bouche H, Pialoux G, et al. Enterocytozoon bienersi infection in acquired immunodeficiency syndrome-related sclerosing cholangitis. *Gastroenterology.* 1992;102(5):1778-1781.
  17. Hashmey R, Smith NH, Cron S, Graviss EA, Chappell CL, White AC, Jr. Cryptosporidiosis in Houston, Texas. A report of 95 cases. *Medicine (Baltimore).* 1997;76(2):118-139.
  18. Daly CA, Padley SP. Sonographic prediction of a normal or abnormal ERCP in suspected AIDS related sclerosing cholangitis. *Clin Radiol.* 1996;51(9):618-621.
  19. Da Silva F, Boudghene F, Lecomte I, Delage Y, Grange JD, Bigot JM. Sonography in AIDS-related cholangitis: prevalence and cause of an echogenic nodule in the distal end of the common bile duct. *AJR Am J Roentgenol.* 1993;160(6):1205-1207.
  20. Bilgin M, Balci NC, Erdogan A, Momtahan AJ, Alkaade S, Rau WS. Hepatobiliary and pancreatic MRI and MRCP findings in patients with HIV infection. *AJR Am J Roentgenol.* 2008;191(1):228-232.
  21. Tonolini M, Bianco R. HIV-related/AIDS cholangiopathy: pictorial review with emphasis on MRCP findings and differential diagnosis. *Clin Imaging.* 2013;37(2):219-226.
  22. Carucci LR, Halvorsen RA. Abdominal and pelvic CT in the HIV-positive population. *Abdom Imaging.* 2004;29(6):631-642.
  23. Forbes A, Blanshard C, Gazzard B. Natural history of AIDS related sclerosing cholangitis: a study of 20 cases. *Gut.* 1993;34(1):116-121.
  24. Chapman RW. Aetiology and natural history of primary sclerosing cholangitis—a decade of progress? *Gut.* 1991;32(12):1433-1435.
  25. Keaveny AP, Karasik MS. Hepatobiliary and pancreatic infections in AIDS: Part one. *AIDS Patient Care STDS.* 1998;12(5):347-357.
  26. Checkley W, White AC, Jr., Jaganath D, Arrowood MJ, Chalmers RM, Chen XM, Fayer R, et al. A review of the global burden, novel diagnostics, therapeutics, and vaccine targets for cryptosporidium. *Lancet Infect Dis.* 2015;15(1):85-94.
  27. Rossignol JF, Kabil SM, el-Gohary Y, Younis AM. Effect of nitazoxanide in diarrhea and enteritis caused by *Cryptosporidium* species. *Clin Gastroenterol Hepatol.* 2006;4(3):320-324.
  28. Amadi B, Mwiya M, Sianongo S, Payne L, Watuka A, Katubulushi M, Kelly P. High dose prolonged treatment with nitazoxanide is not effective for cryptosporidiosis in HIV positive Zambian children: a randomised controlled trial. *BMC Infect Dis.* 2009;9:195.
  29. Hewitt RG, Yiannoutsos CT, Higgs ES, Carey JT, Geiseler PJ, Soave R, Rosenberg R, et al. Paromomycin: no more effective than placebo for treatment of cryptosporidiosis in patients with advanced human immunodeficiency virus infection. *AIDS Clinical Trial Group. Clin Infect Dis.* 2000;31(4):1084-1092.
  30. Cabada MM, White AC, Jr. Treatment of cryptosporidiosis: do we know what we think we know? *Curr Opin Infect Dis.* 2010;23(5):494-499.
  31. Oku T, Maeda M, Waga E, Wada Y, Nagamachi Y, Fujita M, Suzuki Y, et al. Cytomegalovirus cholangitis and pancreatitis in an immunocompetent patient. *J Gastroenterol.* 2005;40(10):987-992.
  32. Molina JM, Oksenhendler E, Beauvais B, Sarfati C, Jaccard A, Derouin F, Modai J. Disseminated microsporidiosis due to *Septata intestinalis* in patients with AIDS: clinical features and response to albendazole therapy. *J Infect Dis.* 1995;171(1):245-249.
  33. Deodhar L, Maniar JK, Saple DG. Cyclospora infection in acquired immunodeficiency syndrome. *J Assoc Physicians India.* 2000;48(4):404-406.
  34. Sifuentes-Osornio J, Porras-Cortes G, Bendall RP, Morales-Villarreal F, Reyes-Teran G, Ruiz-Palacios GM. Cyclospora cayentanensis infection in patients with and without AIDS: biliary disease as another clinical manifestation. *Clin Infect Dis.* 1995;21(5):1092-1097.
  35. Lagrange-Xelot M, Porcher R, Sarfati C, de Castro N, Carel O, Magnier JD, Delcey V, et al. Isosporiasis in patients with HIV infection in the highly active antiretroviral therapy era in France. *HIV Med.* 2008;9(2):126-130.
  36. Castiella A, Iribarren JA, Lopez P, Arrizabalaga J, Rodriguez F, von Wichmann MA, Arenas JI. Ursodeoxycholic acid in the treatment of AIDS-associated cholangiopathy. *Am J Med.* 1997;103(2):170-171.
  37. Casseb J, Fonseca LA, Veiga AP, de Almeida A, Bueno A,



- Ferez AC, Gonsalez CR, et al. AIDS incidence and mortality in a hospital-based cohort of HIV-1-seropositive patients receiving highly active antiretroviral therapy in Sao Paulo, Brazil. *AIDS Patient Care STDS*. 2003;17(9):447-452.
38. Palella FJ, Jr., Delaney KM, Moorman AC, Loveless MO, Fuhrer J, Satten GA, Aschman DJ, et al. Declining morbidity and mortality among patients with advanced human immunodeficiency virus infection. HIV Outpatient Study Investigators. *N Engl J Med*. 1998;338(13):853-860.
39. Maggi P, Larocca AM, Quarto M, Serio G, Brandonisio O, Angarano G, Pastore G. Effect of antiretroviral therapy on cryptosporidiosis and microsporidiosis in patients infected with human immunodeficiency virus type 1. *Eur J Clin Microbiol Infect Dis*. 2000;19(3):213-217.
40. Miao YM, Awad-El-Kariem FM, Franzen C, Ellis DS, Muller A, Counihan HM, Hayes PJ, et al. Eradication of cryptosporidia and microsporidia following successful antiretroviral therapy. *J Acquir Immune Defic Syndr*. 2000;25(2):124-129.
41. Carr A, Marriott D, Field A, Vasak E, Cooper DA. Treatment of HIV-1-associated microsporidiosis and cryptosporidiosis with combination antiretroviral therapy. *Lancet*. 1998;351(9098):256-261.
42. Datta J, Shafi BM, Drebin JA. Extrahepatic cholangiocarcinoma developing in the setting of AIDS cholangiopathy. *Am Surg*. 2013;79(3):321-322.
43. Charlier C, Lecuit M, Furco A, Estavoyer JM, Lafeuillade A, Dupont B, Lortholary O, et al. Cholangiocarcinoma in HIV-Infected patients with a history of Cholangitis. *J Acquir Immune Defic Syndr*. 2005;39(2):253-255.
44. Mangeya N, Mafukidze AT, Pascoe M, Mbuwayesango B, Madziva D, Ndlovu N, Corbett EL, et al. Cholangiocarcinoma presenting in an adolescent with vertically acquired HIV infection. *Int J STD AIDS*. 2008;19(10):717-718.
45. Ko WF, Cello JP, Rogers SJ, Lecours A. Prognostic factors for the survival of patients with AIDS cholangiopathy. *Am J Gastroenterol*. 2003;98(10):2176-2181.